

General Surgical Conditions in the Neonate

Kathy Leack MS RN

General Surgery Clinical Nurse Specialist

Children's Hospital of Wisconsin

Milwaukee, Wisconsin



Goals of this discussion

- To review several general surgical conditions
 - Atresias
 - Intestinal: Duodenal, Jejuno-ileal, Colonic
 - Esophageal Atresia w/ or w/o Tracheoesophageal Fistula
 - Hirschsprung's Disease
 - Imperforate Anus
 - Necrotizing Enterocolitis
 - Omphalocele
 - Gastroschisis
 - Congenital Diaphragmatic Hernia
- Areas to be discussed include:
 - Description of defect and incidence
 - Embryology
 - Clinical presentation
 - Physical examination findings
 - Treatment
 - Complications
 - Nursing responsibilities
 - Family education



Where should we start?

- A term to get us going.....
- ATRESIA
 - “Lack of Lumen”
 - Absence or closure of a natural passage of the body.
 - Blocked or missing
 - A lack of embryological development, which results in the absence of a normal opening.



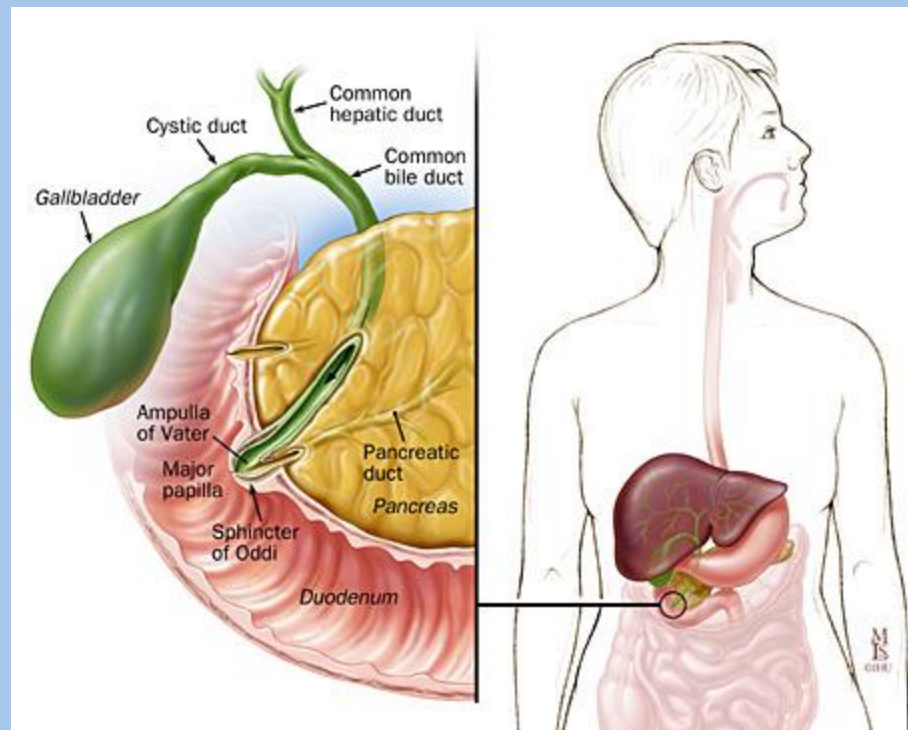
Atresias

- Intestinal Atresia
 - Duodenal Atresia
 - Jejunio-ileal Atresia
 - Colonic Atresia
 - “Anal Atresia” – Imperforate Anus
- Esophageal Atresia
 - With or without Tracheoesophageal Fistula



Duodenal Atresia (& other duodenal issues): More terms for this section

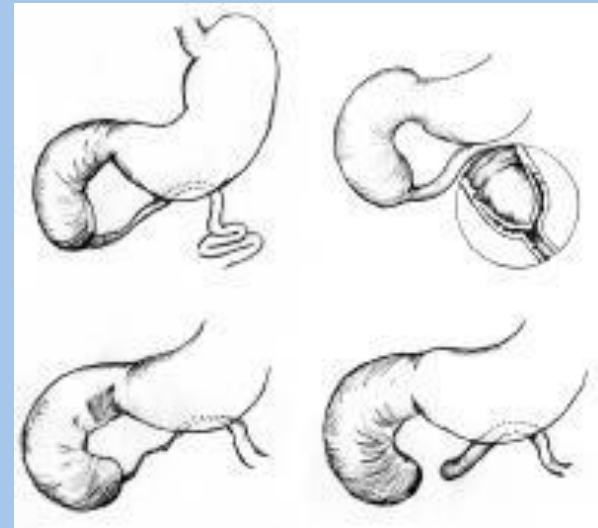
- Duodenum
 - The duodenum is a hollow jointed tube that connects the stomach to the jejunum.
 - It is the first part of the small intestine, and is about 18 cm (7 in) long.
 - Two very important ducts open into the duodenum, namely the bile duct and the pancreatic duct.
- Ampulla of Vater
 - The location at which the common bile duct and pancreatic duct deliver their contents into the duodenum.



Duodenal Atresia

Description

- Duodenal atresia represents complete obliteration of the duodenal lumen.
- Duodenal stenosis is an incomplete obstruction of the duodenal lumen.



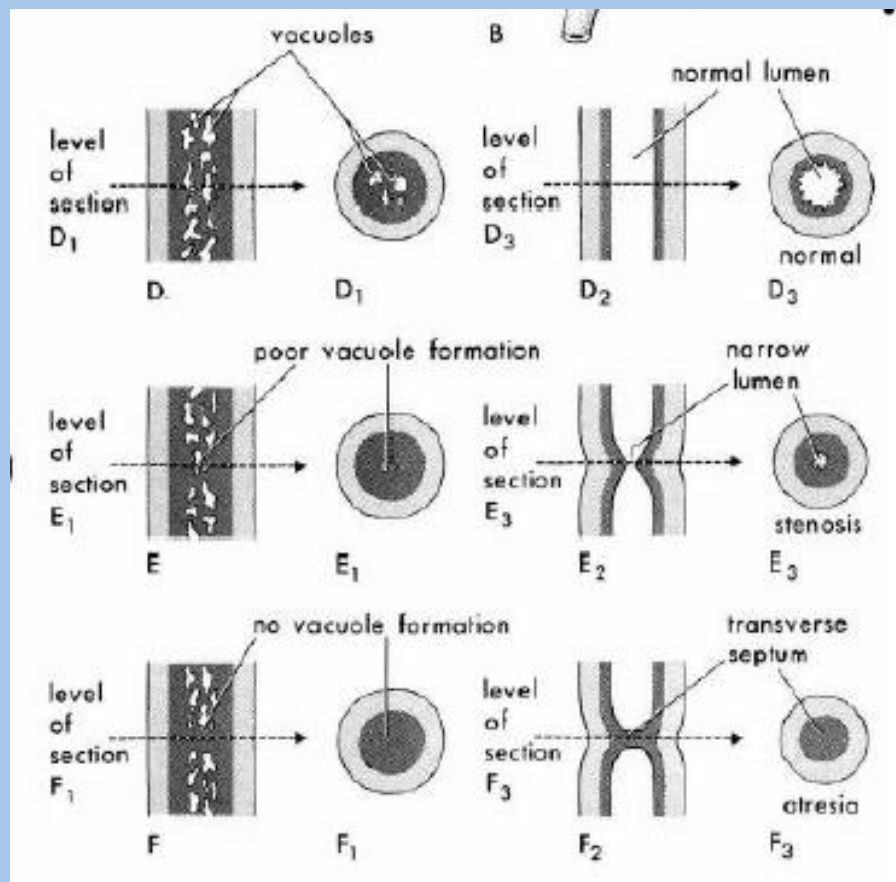
Duodenal Atresia

- Incidence: Occurs with an incidence of 1 per 6000 births.
 - duodenal atresia, 40-60%
 - duodenal webs, 35-45%
 - annular pancreas, 10-30%
 - duodenal stenosis, 7-20%)
- Associated Defects: 30-50%
 - Trisomy 21
 - Cardiac defects
 - Hirschsprung's disease
 - Esophageal atresia: 7-12%
 - Other GI anomalies: anorectal anomalies, intestinal atresias, cloacal anomalies
- Male = Female
- Race: No racial predilection exists
- Age:
 - Infants with duodenal atresia present with vomiting in their first few hours of life.
 - Patients with duodenal stenosis present at various ages. The clinical findings depend on the degree of stenosis. Occasionally, with web or stenosis, presentation may be delayed and may even occur in adults.

Duodenal Atresia

Embryology

- At one point in gestation, the duodenum is a solid structure. During the 8th-10th weeks of gestation, a vacuolation (recanalization) process occurs whereby the duodenum becomes a hollow structure. Failure of the vacuolation process may result in duodenal atresia and stenosis.



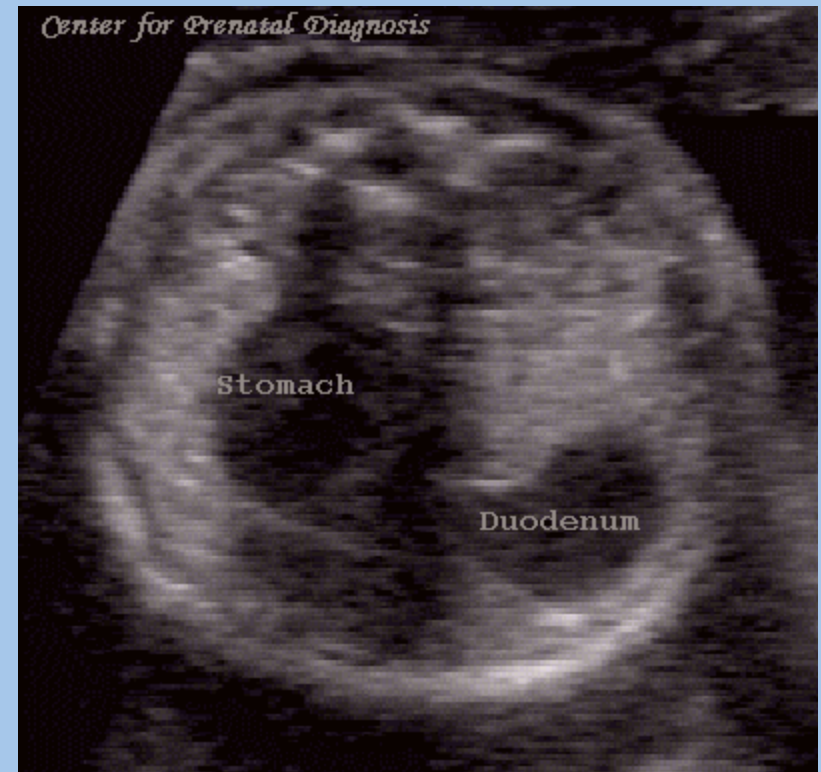Duodenal Atresia

Prenatal Diagnosis

- Polyhydramnios is present in approximately 40% of neonates with duodenal obstruction.
- Ultrasonography demonstrates a dilated, fluid filled stomach and proximal duodenum.

Prenatal Treatment

- Amniotic fluid reduction
- Karyotyping of amniotic fluid to rule out Trisomy 21



Duodenal Atresia

- Clinical Presentation
 - Fullness in epigastrium d/t upper GI tract obstruction (remainder of abdomen is flat or scaphoid)
 - Vomiting (generally bilious as atresia usually occurs below location of ampula)
- Physical Examination
 - Following delivery, a thorough physical examination should be performed, including careful examination of the anus.
 - Evaluation for signs of Trisomy

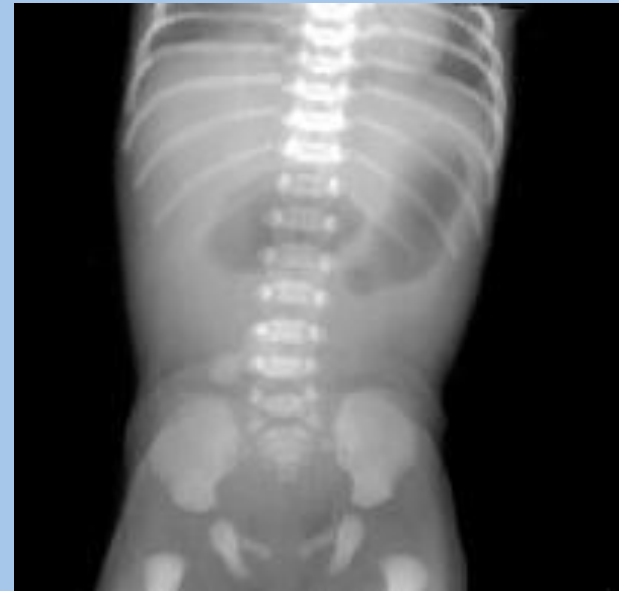

Duodenal Atresia

Radiologic Work Up

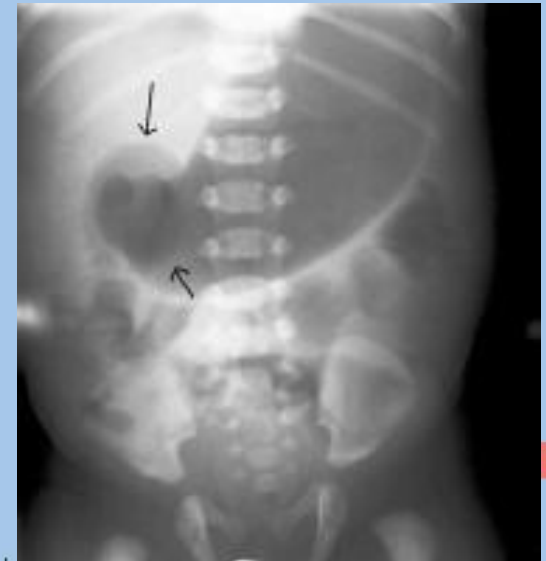- Plain radiographs that demonstrate the double bubble appearance with no distal gas are characteristic of duodenal atresia.
- A “double bubble” sign combined with a gasless abdomen is diagnostic.

- Anteroposterior (AP) radiograph of abdomen depicts the double bubble sign in duodenal atresia.



Duodenal Stenosis

- CAUTION: If distal bowel gas is seen!
 - Midgut volvulus needs to be ruled out!
- Stenosis: Incomplete obstruction of the lumen.
- Distal bowel gas indicates stenosis with an incomplete membrane (windsock deformity).
- Upper gastrointestinal contrast study
 - If a scattered small amount of air is observed distal to the obstruction, duodenal stenosis may be present or other causes of partial intestinal obstruction may exist.
- Anteroposterior (AP) radiograph demonstrates an enlarged duodenum, which represents duodenal stenosis. Air is observed distally.



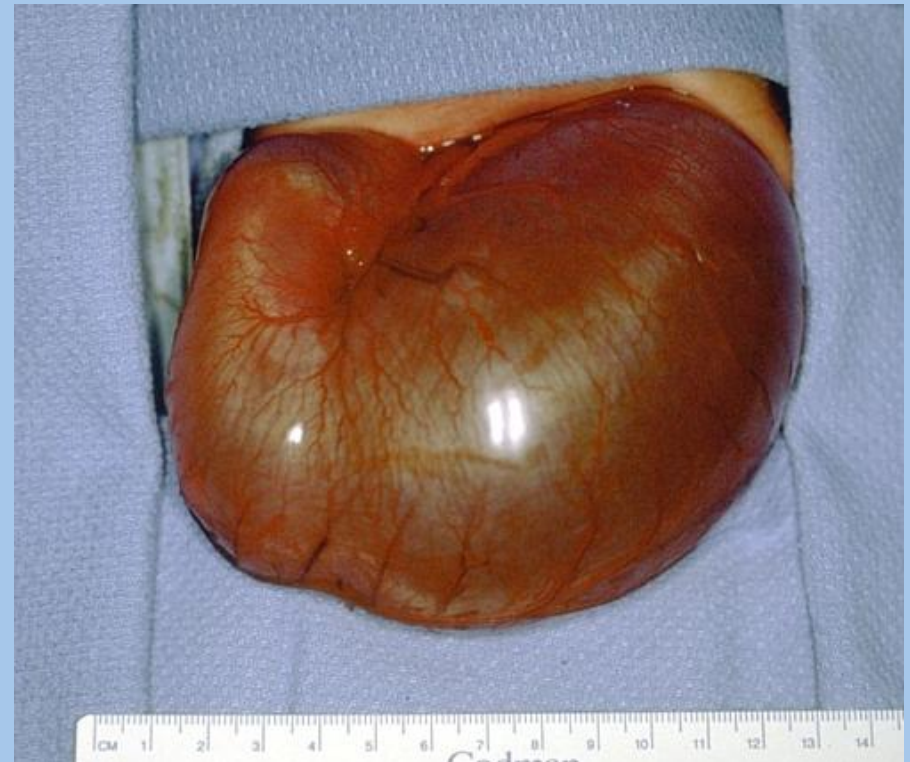Duodenal Atresia

- Newborn Management
 - Respiratory support
 - One half of the neonates with duodenal atresia or stenosis are born prematurely.
 - Venous access
 - Gastric decompression
 - Placement of orogastric tube
 - Gastric distension can compromise ventilatory efforts
 - Fluid Resuscitation
 - Broad spectrum antibiotic coverage
 - Prevention of hypothermia
 - Diagnosis and work-up of associated anomalies
 - ECHO for cardiac anomalies
 - VATER evaluation
 - Karyotype screening for Trisomy



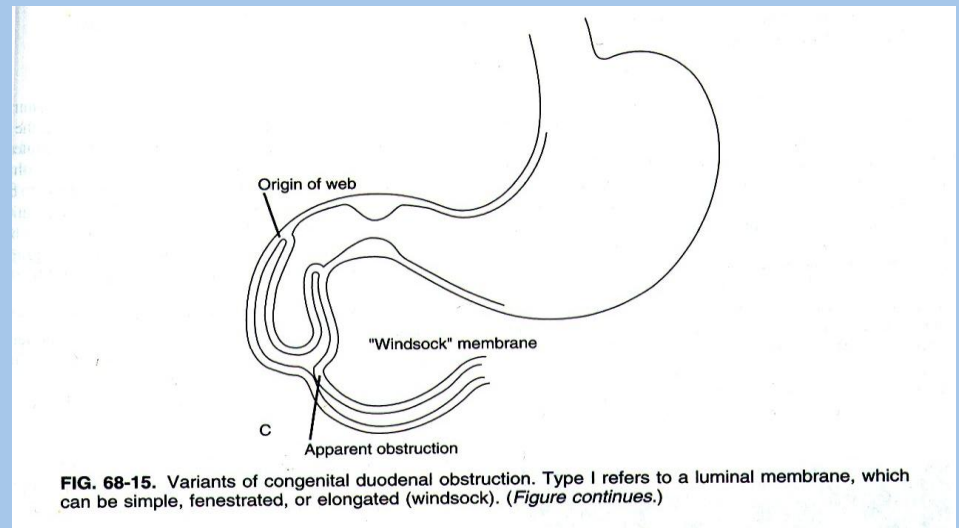
Duodenal Atresia

- Operative photograph shows the massive fluid filled stomach (on the left) and duodenal bulb (on the right)



Duodenal Atresia vs. Stenosis

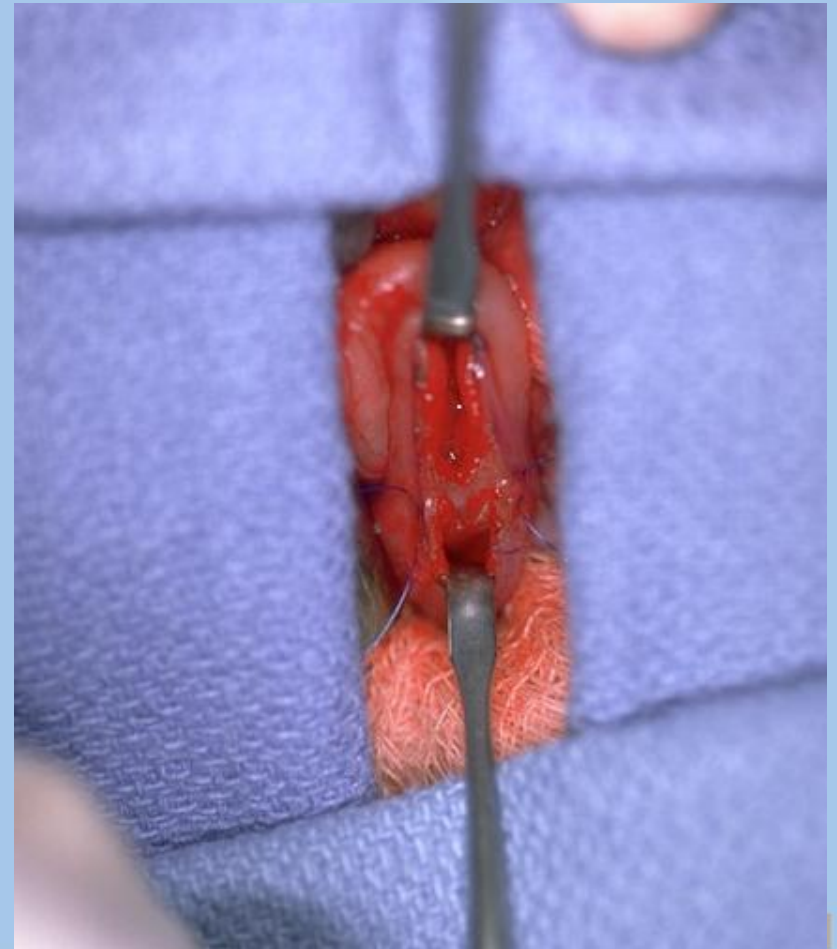- The site of obstruction is detected by the discrepancy in the size of the bowel above and below the obstruction and by passing the orogastric tube down to the level of the obstruction.
- In patients with a windssock web, one may observe an indentation at a site proximal to the site of obstruction. This marks the site of origin of the web and the location where the duodenotomy should be made.



Duodenal Atresia

Treatment - Operative

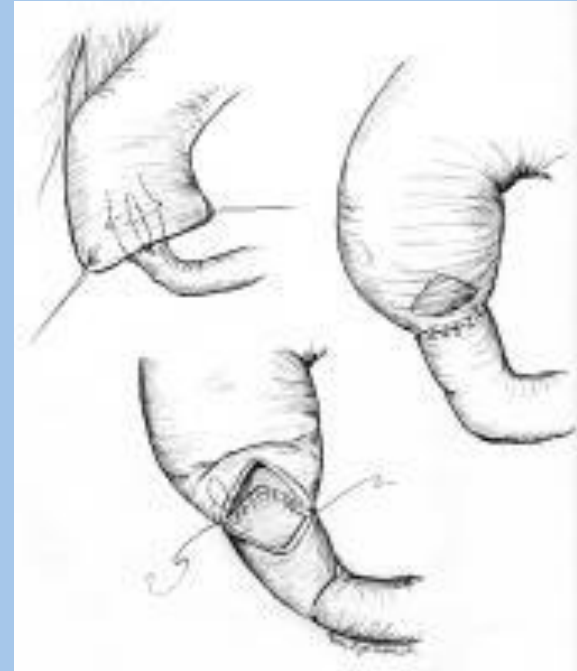- An operative photograph shows the superior retractor distracting the proximal duodenum and the inferior retractor distracting the distal duodenum. The membrane is seen between the retractors.



Duodenal Atresia

Treatment

- Procedure for duodenal atresia is a duodenoduodenostomy
- Duodenal atresia and stenosis: surgical perspective. During the diamond-shaped anastomosis, a proximal transverse to distal longitudinal anastomosis is performed; the midpoint of the proximal incision is approximated to the end of the distal incision.



Duodenal Atresia

- Postoperative care
 - Cardiopulmonary support
 - Gastric decompression
 - Central access
 - Prevention of sepsis
 - Nutritional support
 - Parenteral support
 - Comfort
- Enteral Feeding
 - May have water soluble contrast study POD #5-7 to evaluate healing of anastomosis
 - Watch quantity and character of NG drainage
 - May have high residuals due to large, poorly functioning duodenum – this gradually resolves (may need to “accept” larger residuals with feeding process)



Duodenal Atresia

Complications

- Fourteen to 18% of patients develop postoperative complications, some requiring reoperation. Possible indications for reoperation include anastomotic leak, functional duodenal obstruction, adhesions, and missed atresias.
- Early postoperative complications are frequently related to prematurity, coexisting congenital anomalies, and parenteral nutrition.

Mortality

- Current survival rates for infants with duodenal atresia or stenosis are 95%. Higher mortality rates are associated with prematurity and multiple congenital abnormalities.



Duodenal Atresia

- Family Education
 - Prenatal
 - Preoperative
 - Postoperative
 - Home Care Issues
 - G-tube
- Long Term Issues
 - Gastroesophageal reflux
 - Intestinal obstruction
 - Issues related to Trisomy & other anomalies



Jejuno-ileal Atresia:

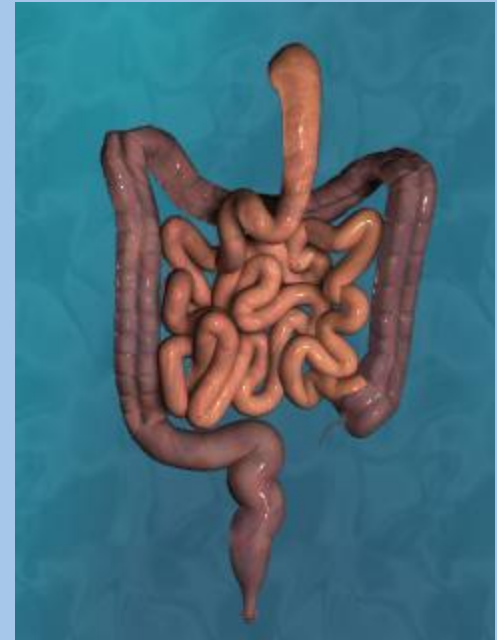Two more terms for this section

Jejunum

- The middle section of the small intestine.
- The second part, arbitrarily the upper two-fifths, of the small bowel, connecting the duodenum with the lower three-fifths (ileum) which gradually becomes histologically distinct.

Intestinal vascular accident

- Interruption to the blood supply to the intestine, whether by clot or prolonged spasm.



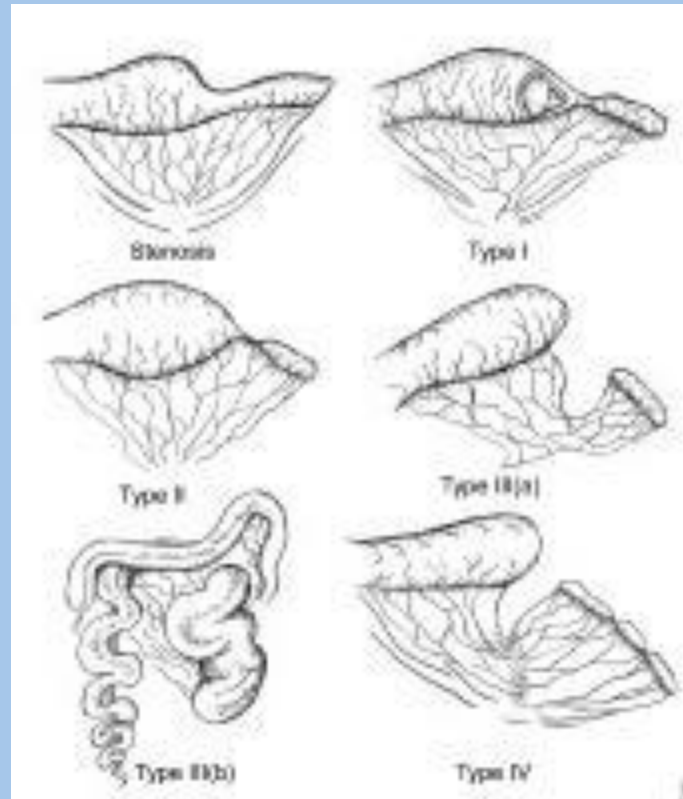
Jejuno-ileal Atresia

Description / Etiology:

- Lack of lumen in the jejunum/ileum
- The most accepted theory regarding the etiology of jejunoileal atresia is that of an intrauterine vascular accident resulting in necrosis of the affected segment with subsequent resorption.
- Incidence:
 - 1 out of every 1500 live births.
 - Distribution of atresias within the small intestine
 - 50% in the duodenum
 - 36% in the jejunum
 - 14% in the ileum.
- Male = Female
- Associated Defects:
 - Cystic Fibrosis (11-25%)
 - SGA
 - Meconium peritonitis/ileus
 - Resultant short gut syndrome



Types of Jejunio-ileal Atresia

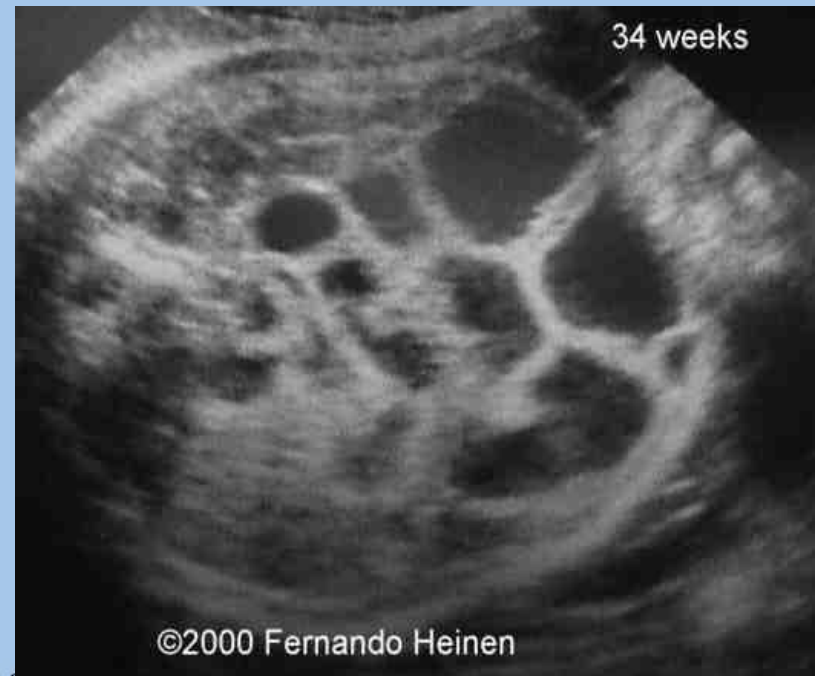

Jejuno-ileal Atresia

Prenatal Diagnosis

- Sonography demonstrates multiple dilated fluid-filled bowel loops proximal to the stenotic/atretic segment.
- Because amniotic fluid is absorbed in the distal ileum, a maternal history of polyhydramnios is less common in jejunoileal atresia than duodenal atresia.

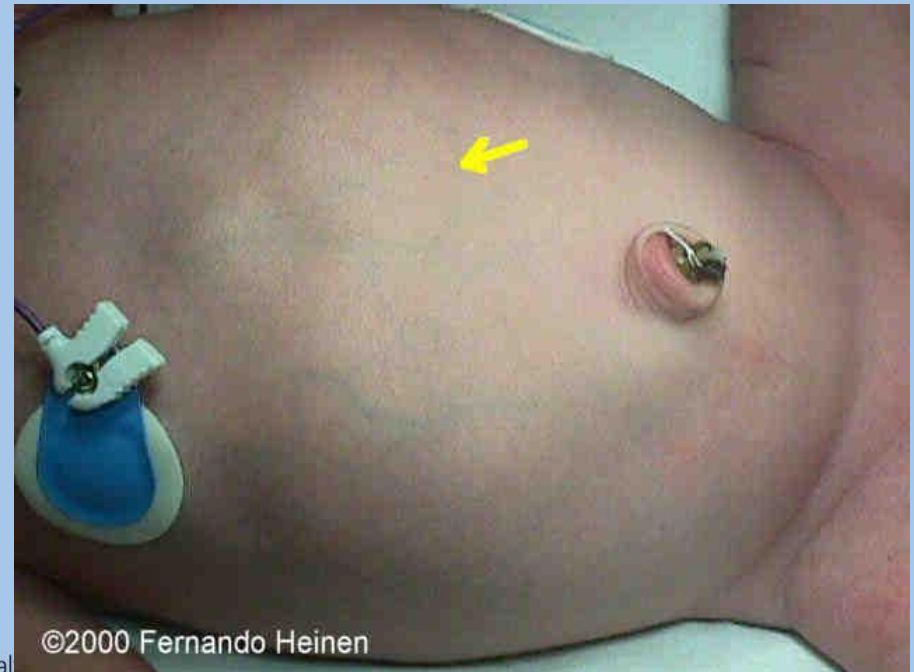The fetal ultrasound at 34 weeks demonstrated moderate polyhydramnios and distended bowel in fetal abdomen.



Jejuno-ileal Atresia

Clinical Presentation

- Neonates with a proximal atresia develop bilious emesis within hours, whereas patients with more distal lesions may take longer to begin vomiting.
- Jaundice and failure to pass meconium. However, the passage of meconium does not rule out intestinal atresia because a third of infants with jejunoileal atresia will pass meconium prior to development of obstructive symptoms (r/t late intrauterine intravascular accident).
- Abdominal distension is more pronounced with distal lesions (as compared to proximal duodenal atresia).
- Respiratory distress d/t abdominal distension



Jejuno-ileal Atresia

- Newborn Management
 - Respiratory support
 - Venous access
 - Gastric decompression
 - Placement of orogastric tube
 - Gastric distension can compromise ventilatory efforts
 - Fluid Resuscitation
 - Broad spectrum antibiotic coverage
 - Prevention of hypothermia



Jejuno-ileal Atresia

Radiologic Work Up

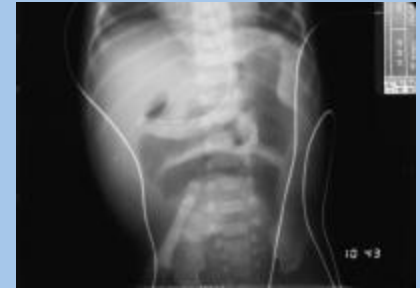With more proximal atresias, few air-fluid levels are evident without apparent gas in the lower part of the abdomen.

The more distal lesions demonstrate more air-fluid levels, but the lower part remains without a gas pattern.

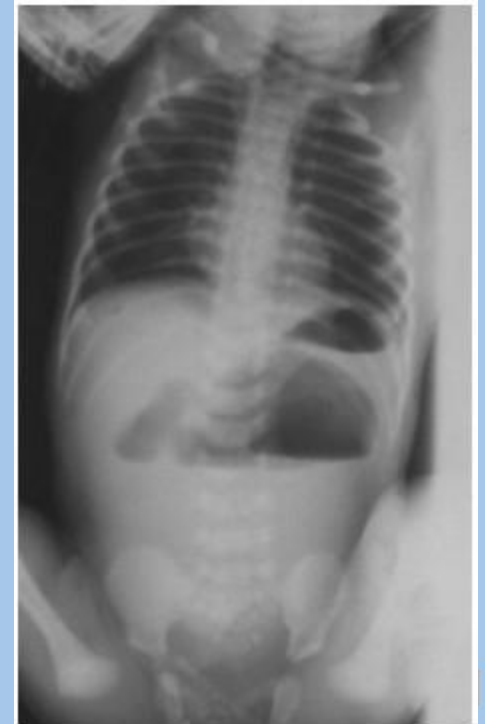
Although a plain radiograph can depict the presence of an obstruction, it is not the best method of showing the location of the abnormality.

Air-fluid levels or peritoneal calcifications may be seen on plain abdominal radiographs. (d/t intrauterine intestinal perforation)

Plain radiograph demonstrating jejunal atresia.



The “triple bubble” sign on the erect plain abdominal radiograph.

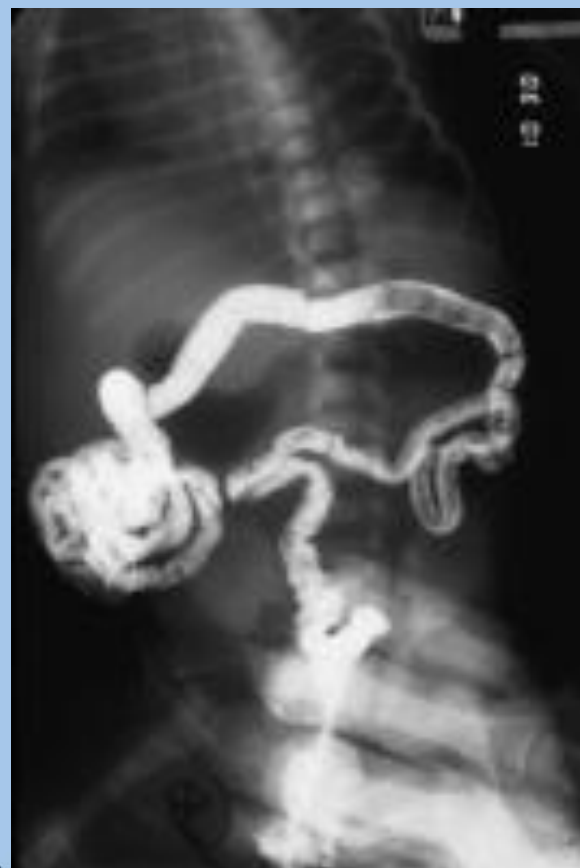


Jejuno-ileal Atresia

Plain lower GI contrast study demonstrating jejunal atresia.

Radiologic Work Up

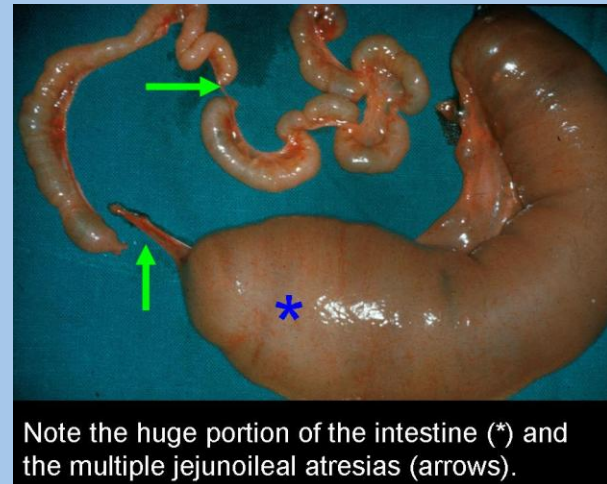
- A barium enema may be used to define a microcolon indicative of a distal small-bowel obstruction.
 - A microcolon is present as no (or minimal) passage of swallowed amnion or meconium has occurred.
- The barium enema is also capable of establishing the diagnosis of other causes of lower obstruction, such as Hirschsprung's disease or a meconium plug.



Jejuno-ileal Atresia

Treatment – Operative

- Definitive treatment requires end-to-end anastomosis of the bowel.




Jejuno-ileal Atresia

Intraoperative Considerations

- The length of intestine that appears functional is measured along the antimesenteric border because bowel length affects the procedure and overall prognosis.
- Since between 6-20% of newborns may have more than one atresia, downstream small intestine must be insufflated with water or air and examined carefully for the presence of another blocked area of intestine.
- Once patency of the entire length of the bowel is established, the repair may proceed.

Post-op Considerations

- The dilated proximal bulb generally does not have normal function and, as a result, abnormal peristalsis may occur postoperatively.



Jejuno-ileal Atresia

- Postoperative care
 - Cardiopulmonary support
 - Gastric decompression
 - Central access
 - Prevention of sepsis
 - Nutritional support
 - Parenteral support
 - Comfort
- Enteral Feeding
 - Initiation of enteral feedings occurs when ileus has resolved.
 - Feeding method influenced by remaining intestinal length.
 - Supplemental TPN required until patient at goal enteral feeds.
 - Assessments of feeding intolerance required – reducing/nonreducing substances, stool output.



Jejuno-ileal Atresia

Complications

Problems where the intestinal ends are joined, such as leak or stricture (narrowing), occur in approximately 5% of cases.

Late diagnosis vs. complication: Stenosis in a neonate is more difficult to diagnose, and it may not manifest for some time. The clinical presentation is dependent on the severity of disease, and these patients have a history of intermittent emesis and failure to thrive. An upper GI with small-bowel follow-through is indicated in these patients.

Mortality

The prognosis for patients with jejunoileal atresia is dependent on the amount of residual functional bowel that exists after surgery.



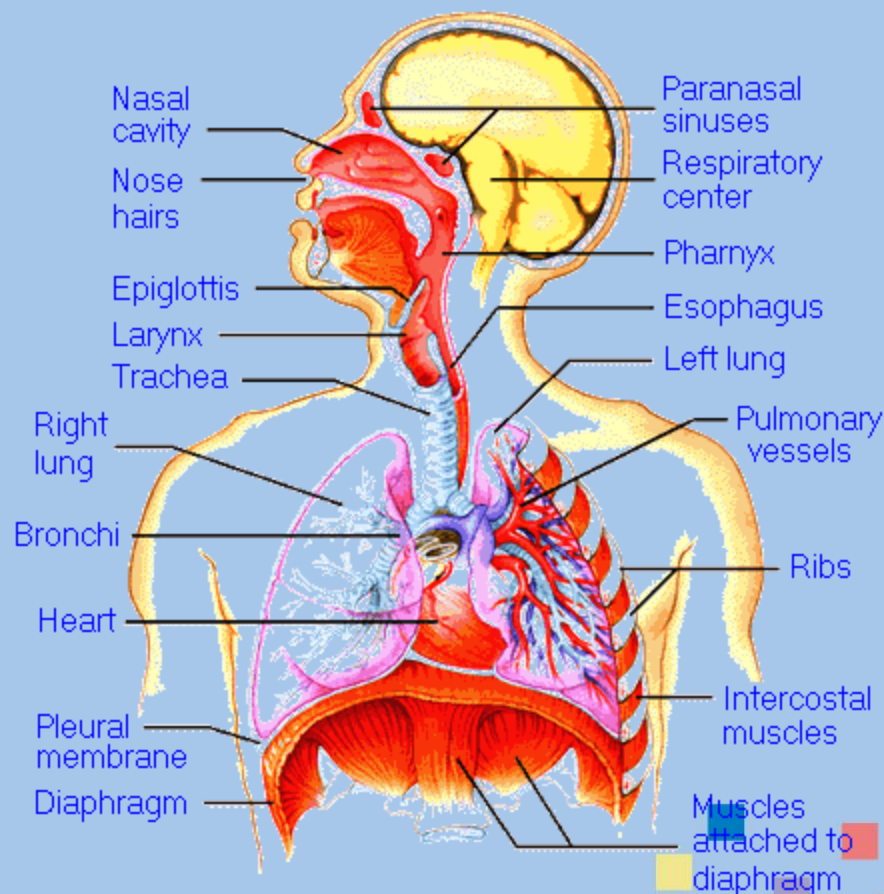
Jejuno-ileal Atresia

- Family Education
 - Prenatal
 - Preoperative
 - Postoperative
 - Prolonged hospitalization
 - Multiple (probable) feeding “set backs”
 - Home Care Issues
 - G-tube
 - CVL/TPN
- Long Term Issues
 - Intestinal obstruction
 - Possible feeding malabsorption with routine childhood illnesses
 - Short-gut issues
 - CVL sepsis
 - TPN cholestasis



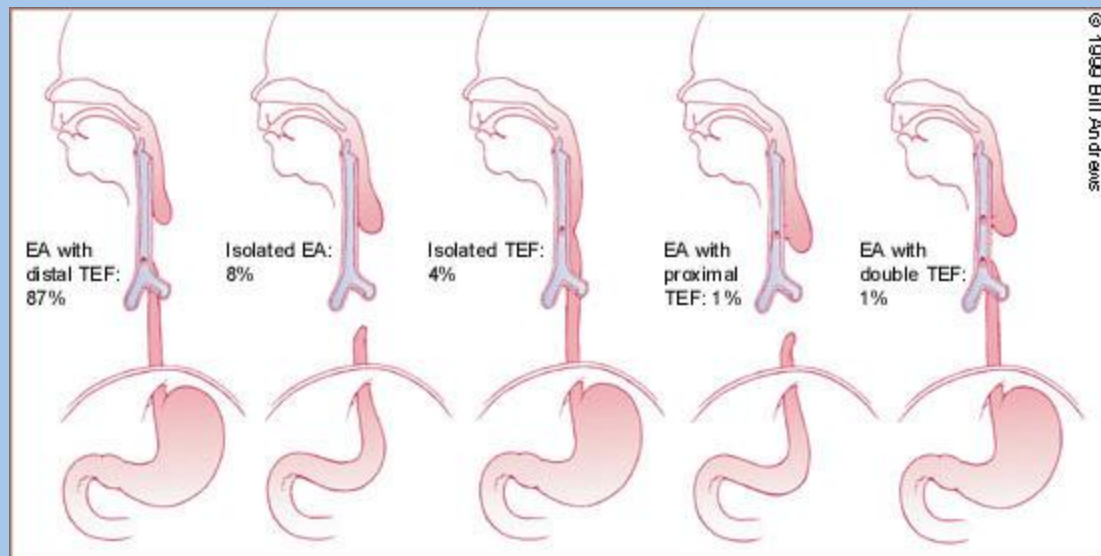
Esophageal Atresia with/without Tracheoesophageal Fistula: concepts for this section

- This is (possibly) a two part diagnosis involving the Esophagus and Trachea
 - Esophagus
 - Swallowing tube made of muscle that connects the throat with the stomach.
 - Trachea
 - The largest breathing tube in the body, passing from the throat down to the chest (where it connects to the two bronchi leading to the lungs).
- Fistula
 - An abnormal passage or communication between two structures



Esophageal Atresia with/without Tracheoesophageal Fistula

- Esophageal Atresia: lack of lumen in the esophagus (blind ending upper pouch)
- Tracheoesophageal fistula: abnormal connection between trachea and esophagus



One more concept:

VATER or VACTERL Syndrome

- V.A.T.E.R./ V.A.C.T.E.R.L. are the acronyms used to describe the types of physical problem(s) a child may have.
- It's an association characterized by the sporadic association of specific birth defects or abnormalities. Not all children born with this association have the same number of abnormalities.

V - Vertebral

- Abnormally formed vertebrae (small (hypoplastic) vertebrae or hemivertebra)
- Extra ribs.

A - Anal Anomalies

- Imperforate anus or other anorectal anomalies

C – Cardiac

- Ventricular septal defect (VSD), atrial septal defects and tetralogy of Fallot.

T - Trachea

- TEF: connection between the trachea and esophagus

E - Esophageal

- Esophageal Atresia

R - Radius (lower arm bone) and/or Renal (kidney)

- Forearm defects: abnormally formed radius or missing thumb
- Abnormally formed kidney, obstruction of outflow of urine from the kidneys or severe reflux

L - Limb (arms, hands, legs or feet)

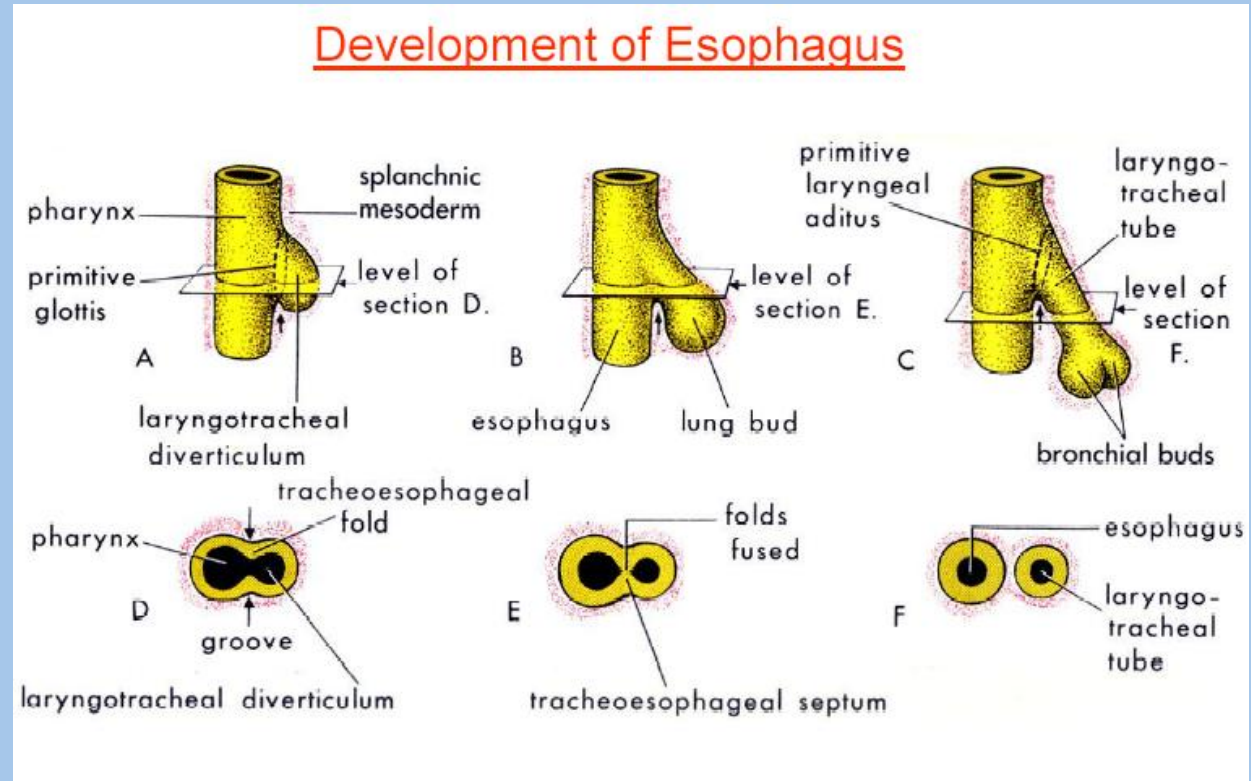
- Absent or displaced thumbs, extra digits (polydactyly), fusion of digits (syndactyly) and forearm defects

Esophageal Atresia with/without Tracheoesophageal Fistula

- Incidence:
 - 1 case in 3000
- Associated Defects:
 - 50-70% of children with EA have some other defect
 - Refer to VACTERL
 - Five percent of these patients have duodenal atresia.
 - Prematurity (EA > EA/TEF)
 - Occurs in multiple births
- Male:Female
 - Males have a slightly increased risk for EA and/or TEF, compared with females.
 - The male-to-female ratio for EA is 1.26, which is significantly higher than the male-to-female ratio of 1.06 in the population.
- Race: has not been associated with any specific race.
- Age: typically diagnosed in neonates within the first few hours of life. Some cases of isolated TEF (H-type), however, are not discovered until early infancy.

Esophageal Atresia with/without Tracheoesophageal Fistula

Embryology:
 Defective division of the embryonic foregut into the trachea and esophagus.



Esophageal Atresia with/without Tracheoesophageal Fistula

Clinical Presentation

- Esophageal Atresia
 - Soon after birth there is excessive drooling due to pooling of secretions in the blind proximal esophageal pouch. Infants cannot clear their secretions.
 - Aspiration of feedings with choking, coughing and cyanosis can occur.
 - Another presentation is failure to pass a nasogastric tube.
- Tracheoesophageal Atresia
 - TEF causes additional complications because of the tracheoesophageal communication. When infants with this anomaly strain, cough, or cry, air enters the stomach through the fistula. As a result, the stomach and small intestine become dilated, elevating the diaphragm and making respiration more difficult (abdominal distension).
 - The reflux of food and gastric secretions may also occur up the esophagus and through the fistula into the tracheobronchial tree; this reflux can contribute to pneumonia and atelectasis. Therefore, pneumonia and respiratory distress are common complications.
- Physical Examination
 - Up to 35 percent of patients with VACTERL association have a single umbilical artery (there are usually two).
 - The abdomen will be scaphoid if no fistula exists.
 - One third of infants with EA weigh less than 2250 GM

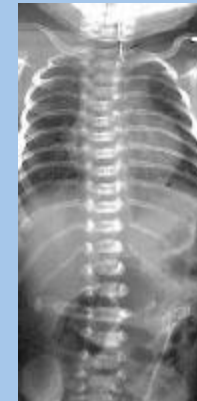

Esophageal Atresia with Tracheoesophageal Fistula (most common)

Radiologic Work Up

- EA with distal TE fistula
 - Gaseous distension of the stomach and small bowel (due to air passing through the fistula) may be observed.
 - Findings confirm a diagnosis of EA by displaying a coiled nasogastric tube in the proximal esophageal pouch of a child with EA.
- The side the aortic arch is on needs to be determined because the surgeon wishes to do their thoracotomy on the side opposite the aortic arch. If the position of the aortic arch cannot be determined from the CXR, an echocardiogram needs to be performed.

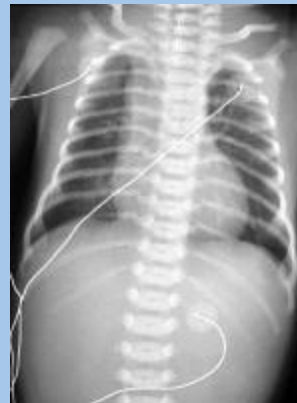Esophageal atresia (EA) with distal tracheoesophageal fistula (TEF). The x-ray demonstrates a tube in the proximal pouch in this patient with EA. The presence of bowel gas implies the presence of a distal TEF, making this the most common type of EA/TEF.



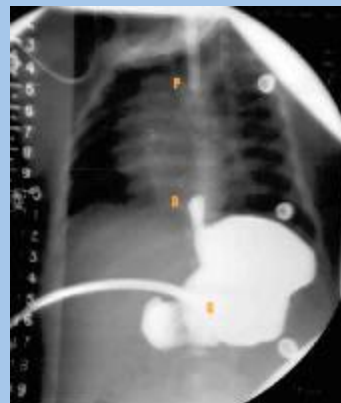(Pure) Esophageal Atresia (2nd most common)

Radiologic Work Up

- Esophageal atresia is visualized on the CXR as a lucent proximal pouch that can displace the trachea anteriorly on the lateral view.
- Isolated atresia
 - Dilated air-filled blind-ending proximal pouch, which often displaces the trachea anteriorly, may be present.
 - Chest images confirm a diagnosis of EA by displaying a coiled nasogastric tube
 - A gasless abdomen may be depicted. Air is normally present in the stomach 15 minutes after birth
 - Lower pouch is visualized with barium or air refluxed through a gastrostomy.



Isolated esophageal atresia (EA). Frontal view of the chest and abdomen demonstrates a catheter in the proximal pouch in this patient with EA. Note the absence of bowel gas in this patient with EA.



Gapogram shows the location of the proximal pouch (*P*), which is suggested by the position of the catheter. The distal pouch location (*D*) is visualized with the reflux of contrast material through a previously placed gastrostomy tube (*G*). The distance between the proximal and distal pouches is measured on the adjacent radiopaque ruler.

Esophageal Atresia with/without Tracheoesophageal Fistula

- Newborn Management...the Replogle Tube!
 - Proximal esophageal pouch decompression
 - Placement of oroesophageal “OE” tube
 - Specific cares: know frequency of tube change, increase in oral secretions requires tube removal – cleansing – and reinsertion
 - Malfunction of the drainage tube can lead to aspiration, desaturation, and bradycardia



Esophageal Atresia with/without Tracheoesophageal Fistula

- Newborn Management
 - Respiratory support
 - Avoid bag/mask ventilation because it may cause abdominal distension r/t TE Fistula
 - Broad spectrum antibiotic coverage (to cover respiratory flora r/t aspiration <TEF>)
 - Evaluation for diagnosis and work-up of associated anomalies
 - VATER evaluation (ECHO, renal US, bone x-rays)
 - Evaluation of umbilical cord/vessels
 - Venous access, Prevention of hypothermia

Esophageal Atresia with/without Tracheoesophageal Fistula

Treatment – Operative

- The severity of associated cardiac disease & need for repair may supercede repair of the esophagus.
- Goal: Primary repair
 - Preservation of native esophageal tissue is superior to anything used to replace it.
- EA/TEF
 - Primary repair includes the ability to get the two ends of the esophagus together and to ligate and divide the fistula.
- Pure Esophageal Atresia
 - Elongation of the proximal pouch occurs as the neonate grows.
 - Attempts at “stretching” the proximal pouch have not been very successful (i.e., bougie dilatation, magnets)
 - Cervical esophagostomy with delayed esophageal repair (intestinal transposition) – usually for patients with multiple complex medical/surgical needs
 - Gastric transposition as esophageal replacement



Esophageal Atresia with/without Tracheoesophageal Fistula

- Postoperative care
 - Cardiopulmonary support
 - Extreme care must be taken if neonate requires reintubation
 - Esophageal sutureline
 - Tracheal sutureline
 - Deep suctioning to be avoided
 - Central access
 - Prevention of sepsis
 - Nutritional support
 - Parenteral support
 - Comfort



Esophageal Atresia with/without Tracheoesophageal Fistula

- Care of “tubes”
 - Chest drain
 - Usually not a “chest tube” as pleura has not been entered during surgery (suction not needed – check if it is ordered)
 - Drain placed near esophageal anastomosis – assess for saliva in drain (anastomotic leak)
 - NG tube
 - Not placed in all instances
 - This is not to be replaced if it is removed (esophageal suture line)
 - Care to protect all tubes
 - Signs posted at bedside about tube “nonreplacement” in the event of accidental removal.
 - Position of head – avoid overextension
 - Gastrostomy tube (placed in EA patients prior to reconstructive surgery); may be placed in patients with EA/TEF & multiple anomalies

Esophageal Atresia with/without Tracheoesophageal Fistula

- Esophagram
 - A contrast esophagram is performed 5-10 days after repair to assess for anastomotic leaks.
 - If no leaks, oral feeds are initiated.
- Enteral Feeding
 - May need to work with Speech Therapist
 - Supplemental GT feeds
- Care of GERD
 - This is exacerbated by poor esophageal peristalsis, shortening of esophagus (tension required to obtain repair)
 - Reflux exacerbates esophageal stricture formation
 - Antacid therapy
 - Reflux feeding precautions




Esophageal Atresia with/without Tracheoesophageal Fistula

Complications

- The severity of complications after EA repair is often dictated by the extent of the repair required. Primary anastomosis and fistula closure has fewer complications than esophageal replacement.
 - Anastamotic leak
 - Esophageal strictures occur in 40%
 - GER is a common complication, occurring in 40-70%
 - Altered esophageal peristalsis (seen in all patients)
 - Tracheomalacia (seen in all patients)
- An esophageal substitution causes additional complications. Esophageal replacement has been associated with an increased surgical morbidity rate and a 68% complication rate.
 - Gastric transposition (Leakage in 6% cases, stricture at the anastomosis in 12% cases, aspiration)
 - Colon (Cervical leaks, redundancy, GER)

Mortality

- Despite an increased number of patients with severe anomalies, survival rates as high as 95% have been reported.
- In uncomplicated cases, survival rates approach 100%.



Esophageal Atresia with/without Tracheoesophageal Fistula

- Family Education
 - Preoperative
 - Upper pouch suctioning
 - Early initiation of Speech Therapy if pt has long gap EA
 - Postoperative
 - Feeding issues
 - Reflux precautions
 - Home Care Issues
 - G-tube, cervical esophagostomy
 - Medications
- Long Term Issues
 - Gastroesophageal reflux
 - Surgical treatment of GERD
 - Esophageal stricture
 - Review S/S: food not passing, difficulty swallowing, increased drooling, refusal to eat
 - Dilation
 - Issues related to associated anomalies



Imperforate Anus (“Anal Atresia”): concept for this section

- Anorectal malformation
 - This term encompasses multiple congenital anomalies of the rectum, urinary and reproductive structures with varying degrees of complexity.
 - Many require different types of treatment with different prognosis for bowel, urinary, and sexual function.
 - Most children have abnormal communication between the rectum, the genitourinary tract or the perineum.
- Therefore, it's more than whether or not an infant has an anal opening.



Imperforate Anus

- **Description**
 - Abnormal separation of the hindgut during fetal development resulting in abnormal location of anorectum and possible fistula with the GU tract

Diagram of imperforate anus and rectourethral fistula.

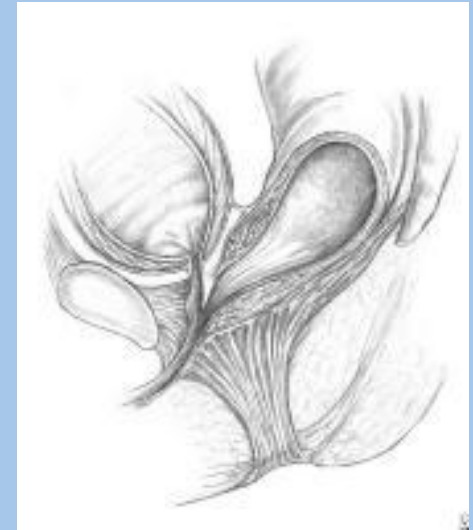
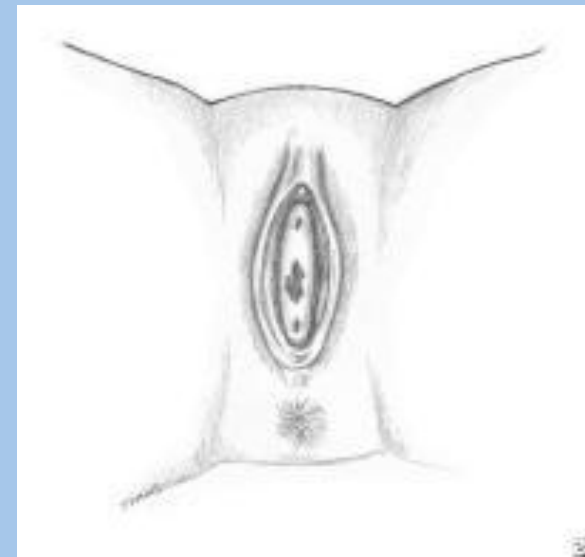
Diagram of an imperforate anus and rectovestibular fistula.



Imperforate Anus

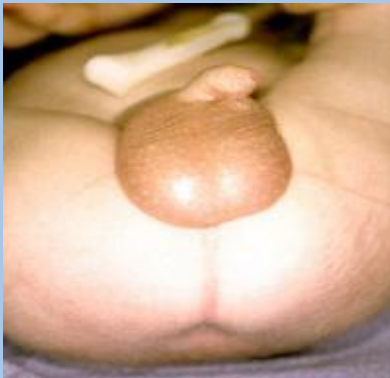- Incidence:
 - Minor abnormalities occur in approximately 1 per 500 live births
 - Major anomalies occur in 1 per 5000 live births.
 - Some families have a genetic predisposition, and successive generations have anorectal malformations.
- Associated Defects:
 - Refer to VACTERL
- Male:Female
 - Most studies report a male preponderance of 55-65%.
 - High anomalies occur more often in males, while low lesions occur more often in females
- Race: No racial differences
- Age:
 - Routine newborn examinations usually detect anorectal anomalies early in life.
 - Some types of malformations (e.g., anterior ectopic anus, anal stenosis) are less readily detected. Patients may present with these lesions much later with a history of chronic constipation or pain.

Anorectal malformation classification

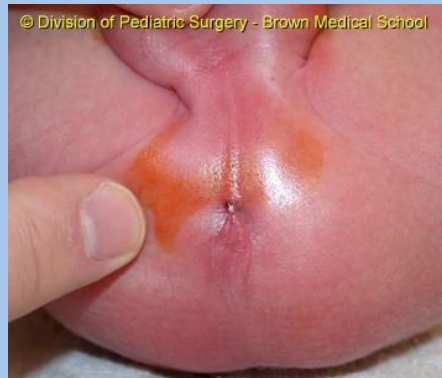- The most useful clinical classification categorizes lesions by whether the rectum passes through the puborectalis/levator muscle sling/complex
 - High lesions fail to pass through this muscle complex and are more likely to elicit long-term continence problems. These lesions typically include a fistula from the atretic rectum and the genitourinary tract.
 - Low lesions traverse this muscle complex, and patients with these conditions generally have a better prognosis. Infralevator lesions (ie, low) are more likely to have perineal or posterior fourchette fistulas.



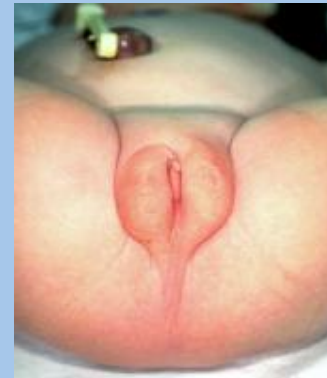Anorectal Malformation: High Lesions



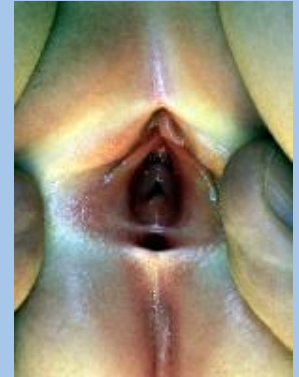Newborn boy
with imperforate
anus.



Newborn with
imperforate anus
and a rectoperineal
fistula.



Imperforate anus
and rectovestibular
fistula in a newborn.



Imperforate Anus

Physical Examination

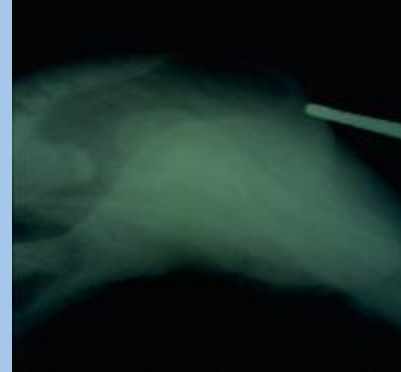
- Clinical inspection of the buttocks is important.
 - Absent or anomalous anal opening
 - Fistulous tract in the region of the perineal body
 - +/- developed buttocks
- Findings are associated with a high malformation:
 - A flat bottom “rocker bottom” or flat perineum, as evidenced by the lack of a midline gluteal fold and the absence of an anal dimple, indicates that the patient has very poor muscles in the perineum.
 - Passage of meconium or flatus via the urinary tract
- Perineal signs found in patients with low malformations:
 - The presence of meconium at the perineum
 - A bucket-handle malformation (i.e., a prominent skin tag located at the anal dimple, below which an instrument can be passed)
 - An anal membrane (through which one can see meconium).



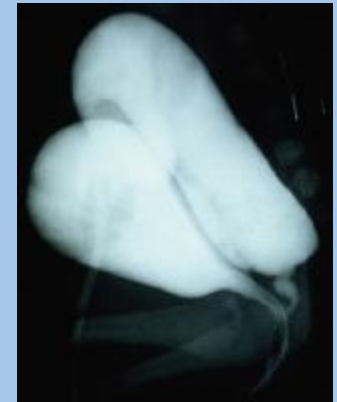Imperforate Anus

Radiologic Work Up

- A cross table lateral film is obtained with the infant in the prone position with the pelvis elevated. The gas inside the distended blind rectum give a radiolucent image. The distance between the radiopaque marker on the skin and the blind rectum is measured to provide information about the level of the defect.
- A distal colostogram is obtained before the PSARP to determine the location of the most distal part of the bowel and the location, if present, of a fistula between the bowel and urogenital tract.



Cross table lateral radiograph of a patient in which the air column in the distal rectum can be observed close to the perineal skin.



Distal colostogram of a patient with imperforate anus and a rectourethral fistula.

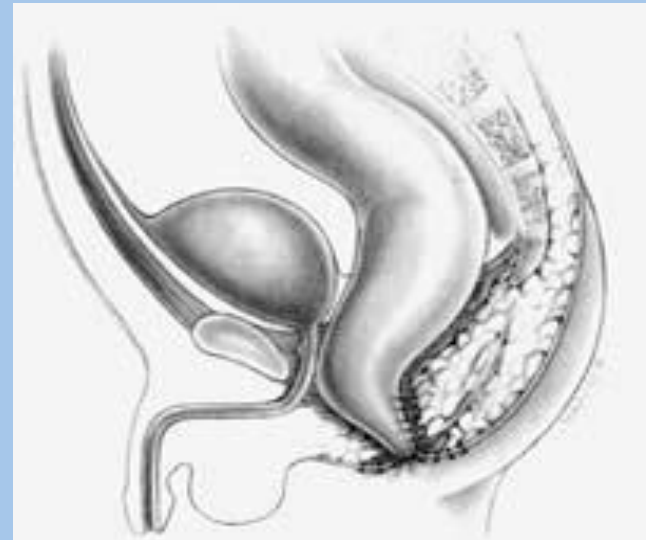Imperforate Anus

- Newborn Management
 - Respiratory support
 - A nasogastric tube is inserted to keep the stomach decompressed.
 - Urinalysis and a gauze placement over the penis can be done to determine the presence of fecal matter in the urine, which is considered evidence of a rectourinary fistula.
 - Evaluation for diagnosis and work-up of associated anomalies
 - VATER evaluation (ECHO, renal US, bone x-rays)
 - Eval of umbilical cord/vessels
 - Venous access
 - Prevention of hypothermia (especially during radiologic testing and evaluation of bottom)

Imperforate Anus

Operative Treatment — Low Lesions

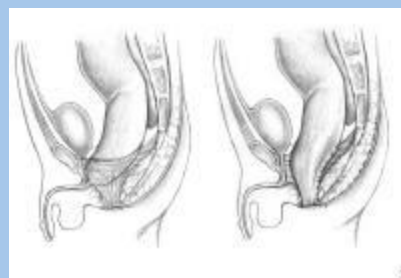- Rectoperineal fistula
- Anterior displaced anus
- Ectopic anus
- Anoplasty
 - The surgical procedure involves moving the fistula opening into a posterior/anatomically correct position at the center of the sphincter and creating a larger anal opening.
 - Completed in the newborn period.



Imperforate Anus

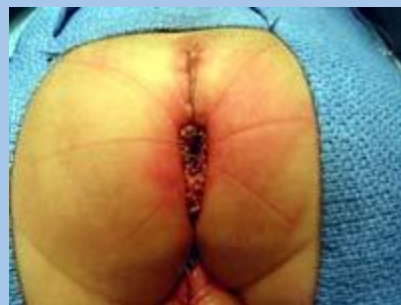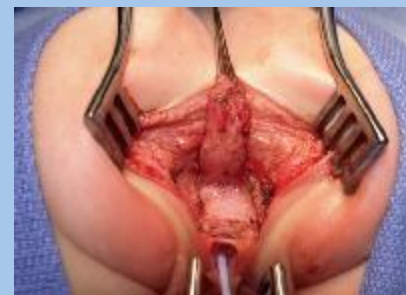Operative Treatment — High Lesions

- A colonic diversion is recommended for patients with high lesions until later definitive repair can be achieved.
- Posterior sagittal anorectoplasty (PSARP)
 - This approach is from the midline.
 - The individual components of the muscle complex and end portion of the rectum are identified.
 - The fistulous connection to the genitourinary tract usually is identified and corrected.
 - Electrical stimulation of the external anal sphincters and levator muscle complex is mandatory for proper reconstruction.



Before and after schematic diagram of the anatomy and the repair of a rectourethral anorectal malformation.

Posterior sagittal repair of a rectovestibular fistula.



Imperforate Anus

- Postoperative care
 - Cardiopulmonary support
 - Nothing per rectum
 - Butt cares vs. colostomy cares
 - Comfort
 - Venous Access



Imperforate Anus

Prognosis/Long Term Issues

- Constipation is common after surgical repair. “Bowel management” is a long-term endeavor.
- Some patients develop intractable constipation and require additional procedures.
- Most patients can achieve fecal continence. Of patients with low imperforate anus, 90% have good control; cases involving high lesions are more difficult to predict.
- Constipation and continence have the most impact on lifestyle. Long-term follow up is essential. HIA Clinic follow-up.
- Anal stenosis occurs in as many as 30% of patients and should be closely monitored in the postoperative period. Routine anal dilatation usually obviates this problem.

Morbidity/Mortality

- The lesions in the spectrum covered by the term imperforate anus rarely are fatal, although some associated anomalies can be life threatening.



Imperforate Anus

- Family Education
 - Preoperative
 - Postoperative
 - Home Care Issues
 - “Butt Cares”
 - Anal Dilatations
 - Colostomy Cares
- Long Term Issues
 - Long-term consistent outpatient surgical follow-up care is essential.
 - Constipation and fecal continence
 - Issues related to associated anomalies



Neonatal Intestinal Obstruction

- Malrotation & Midgut Volvulus
- Hirschsprung's Disease
- Necrotizing Enterocolitis
- The “Atresia Family”
- Meconium Ileus, Meconium Plug Syndrome



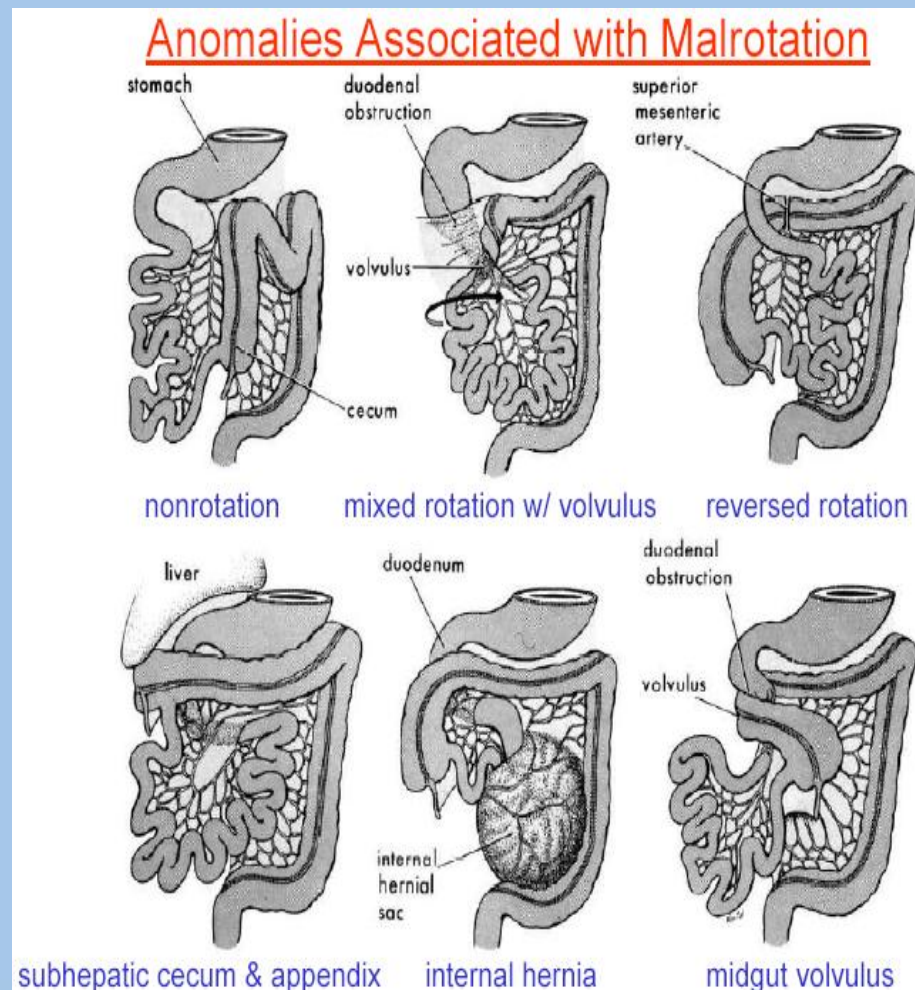
Neonatal Intestinal Obstruction

- There are several anatomic defects, metabolic and physiologic disorders associated with intestinal obstruction.
- Intestinal obstruction should be considered when a neonate presents with bilious vomiting with associated abdominal distention.



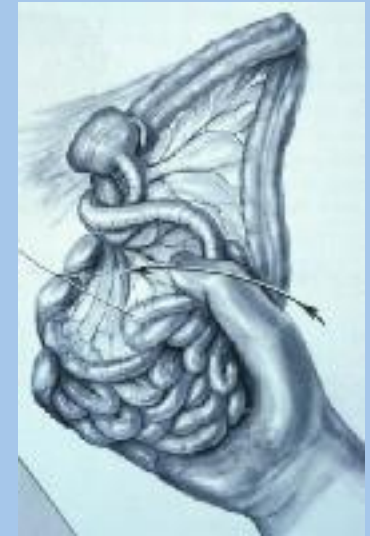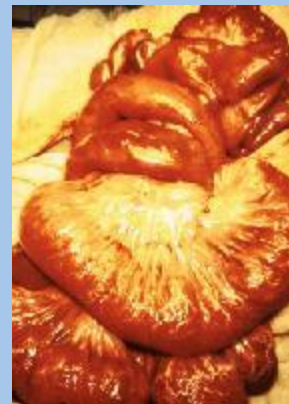Malrotation & Midgut Volvulus

- Failure of mesenteric fixation allowing the small bowel to twist around a narrow mesenteric pedicle.
- Ischemia occurs leading to bowel death.
- A surgical emergency!
- Should be suspected in an otherwise healthy child with new onset bilious vomiting.



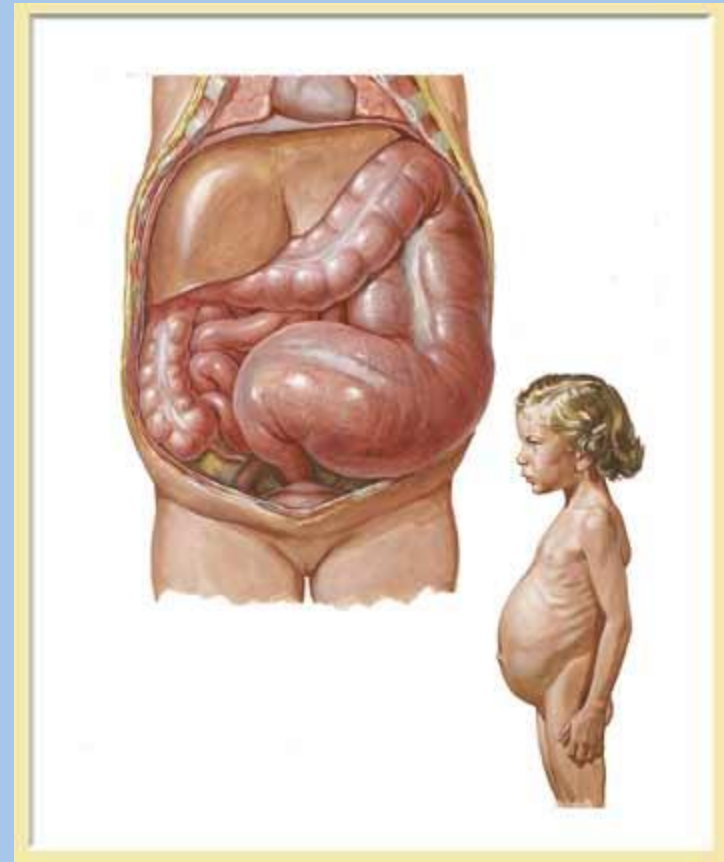
Malrotation & Midgut Volvulus

- Ladd's Procedure
 - Evisceration
 - Reduction/Detorsion of the Volvulus
 - Division of Ladd's Bands
 - Widening of Mesenteric Base
 - Relief of Duodenal Obstruction
 - Incidental Appendectomy



Hirschsprung's Disease

- Description
 - Inadequate intestinal motility is a result of an aganglionic section (without nerve tissue) of the intestines.
 - Usually confined to colon resulting in megacolon (dilated section of colon).
 - However, disease may reach to small intestine (total colon Hirschsprung's).



Hirschsprung's Disease

- Incidence
 - 1 case per 5,000
- Associated conditions
 - Trisomy 21: 12%
 - Multiple endocrine neoplasia type 2 (MEN2)
 - Cat eye syndrome
 - Waardenburg syndrome
 - Bardet-Biedl syndrome
- Male:Female
 - Males are affected more often 4:1
 - The male preponderance for the disease is slightly reduced when only patients with long-segment HD are considered.
- Race
 - 1.5 cases per 10,000 Caucasians
 - 2.1 cases per 10,000 African Americans
 - 2.8 cases per 10,000 Asian Americans.
- Age
 - Usually are diagnosed by age 2 years.
 - Older infants and children with Hirschsprung's disease usually present with chronic constipation.
 - May also present with malnourishment.

Hirschsprung's Disease

Embryology

- HD is characterized by the absence of myenteric and submucosal ganglion cells in the distal alimentary tract. The disease results in decreased motility in the affected bowel segment.

Genetic relationship

- The disease is generally sporadic, though incidence of familial disease has been increasing.
 - A family history of a similar condition is present in about 30% of cases.
- Multiple loci appear to be involved, including chromosomes 13q22, 21q22, and 10q.
- Mutations in the Ret proto-oncogene have recently been associated with multiple endocrine neoplasia (MEN) 2A or MEN 2B and familial Hirschsprung's disease.
- Other genes associated with Hirschsprung's disease include the glial cell-derived neurotrophic factor gene, the endothelin-B receptor gene, and the endothelin-3 gene.

Hirschsprung's Disease

Clinical History

- Failure of passage of meconium within the first 48 hours of life.
- Repeated vomiting & feeding intolerance. (S/S intestinal obstruction)
- Hirschsprung's enterocolitis:
 - Can be a fatal complication of Hirschsprung's disease.
 - Enterocolitis typically presents with abdominal pain, fever, foul-smelling and/or bloody diarrhea, as well as vomiting.
 - If not recognized early, enterocolitis may progress to sepsis, transmural intestinal necrosis, and perforation.

Physical Exam

- Tympanitic abdominal distention and symptoms of intestinal obstruction.
- May also present with acute enterocolitis Children with Hirschsprung's disease On abdominal examination, these children may demonstrate marked abdominal distention with palpable dilated loops of colon. Rectal examination commonly reveals an empty rectal vault and may result in the forceful expulsion of fecal material upon completion of examination.
 - Less commonly, older children with Hirschsprung's disease may be chronically malnourished and/or present with Hirschsprung's enterocolitis.

Hirschsprung's Disease

Newborn Management

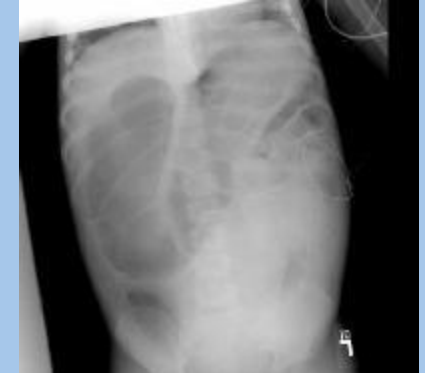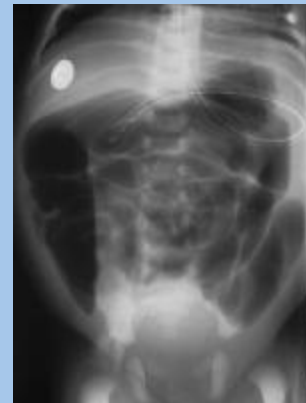
- If the child has symptoms and signs of a high-grade intestinal obstruction, initial therapy should include intravenous hydration, withholding of enteral intake, and intestinal and gastric decompression.
 - Venous access
- Decompression can be accomplished through placement of a nasogastric tube and either digital rectal examination or normal saline rectal irrigations
- Administer broad-spectrum antibiotics to patients with enterocolitis.
- Evaluation for diagnosis and work-up of associated anomalies
 - Trisomy 21 (ECHO)
- Prevention of hypothermia (especially during radiologic testing)

Hirschsprung's Disease

Radiologic Work Up

- Plain abdominal radiography
 - Radiographs of the neonatal abdomen may show:
 - multiple loops of dilated small bowel with air-fluid levels that can usually be determined to be a distal bowel obstruction
 - an empty rectum
 - a cutoff sign in the rectosigmoid region, with an absence of air distally,

- Abdominal radiograph demonstrating small bowel obstruction and megacolon in infant with Hirschsprung's Disease.

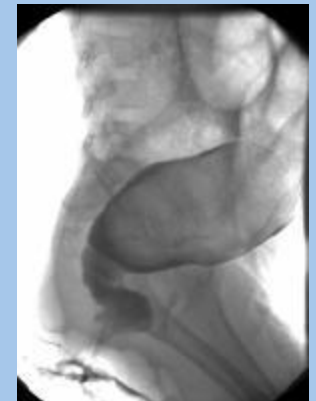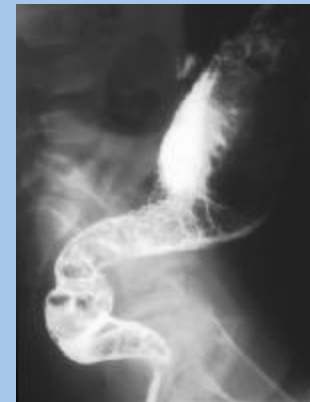


Hirschsprung's Disease

Radiologic Work Up

- Unprepared single-contrast barium enema
 - May help establish the diagnosis by identifying a transition zone between a narrowed aganglionic segment and a dilated and normally innervated segment.
 - A transition zone may not be apparent in neonates due to insufficient time to develop colonic dilation.


- Barium enema demonstrating transition zone. The transition zone shows the transition from dilated, normally innervated bowel to normal caliber, noninnervated bowel.



Hirschsprung's Disease

Diagnostic Procedures:

- Rectal biopsy: The definitive diagnosis of Hirschsprung's disease rests on histological review of rectal tissue.
 - Obtain tissue either by suction rectal biopsy or transanal wedge resection. If a suction biopsy is performed, take the biopsy 2-2.5 cm above the dentate line on the posterior wall to minimize the risk of perforation.
 - Nursing responsibility: Assist with procedure – infant in “frog-legged position”
- Histologic Findings
 - absence of ganglion cells in the myenteric plexus and hypertrophic nerve fibers.
- Classification
 - Classical HD (75% of cases): The aganglionic segment does not extend beyond the upper sigmoid.
 - Long segment HD (20% of cases)
 - Total colonic aganglionosis (3-12% of cases)

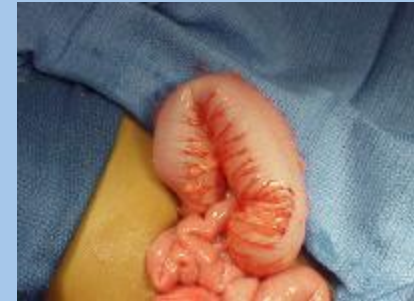

Hirschsprung's Disease

Treatment – Operative Management

- The surgical options vary according to the patient's age, length of the aganglionic segment, degree of colonic dilation, and presence of enterocolitis.
- Surgical options include:
 - Rectal irrigations followed by a pull-through procedure once bowel caliber is restored to normal & enterocolitis has been treated.
 - A staged procedure with placement of a diverting colostomy followed by a pull-through procedure.
- Length of HD cannot be determined until operation; rectal biopsy does not give level of disease – only presence.

- Hirschsprung's disease: intraoperative finding in total colonic aganglionosis. Note the decompressed bowel adjacent to the distended colon.



Pull thru operations include:

- Soave Endorectal Pull Thru (most common)
- Swenson & Duhamel
- Operations can be performed laparoscopically or open

Hirschsprung's Disease

- Postoperative care
 - Cardiopulmonary support
 - Nothing per rectum
 - Butt cares vs. colostomy cares
 - Comfort
 - Venous Access



Hirschsprung's Disease

Complications

- Intermittent fecal soiling and incontinence
- Enterocolitis
 - Colonic lavage may be used in postoperative patients who develop enterocolitis in addition to antibiotics (Flagyl)
 - Injecting the nonrelaxing internal sphincter mechanism with botulinum toxin (Botox) has been shown to induce more normal patterns of bowel movements in postoperative patients with enterocolitis.
- Anastomotic leak
- Stricture formation
- Intestinal obstruction

Prognosis/Long Term Issues

- In general, more than 90% of patients with Hirschsprung's disease have satisfactory outcomes.



Hirschsprung's Disease

Family Education

- Preoperative
 - Preoperatively, counsel the family as to the available surgical options. If the child is to undergo a staged procedure or have a permanent ostomy, provide preliminary instruction about ostomy care to the family.
 - Prior to surgical intervention, irrigations are required to decompress colon.
- Postoperative
 - Home Care Issues
 - “Butt Cares”
 - Colostomy Cares
 - S/S Enterocolitis
- Long Term Issues
 - Long-term consistent outpatient surgical follow-up care is essential.
 - Constipation
 - Enterocolitis
 - Issues related to associated anomalies



Necrotizing Enterocolitis

- The short version...
- Although the exact etiology is still unknown, research suggests that it is multifactorial:
 - Ischemia and/or reperfusion injury may play a role.
 - Cases that cluster in epidemics suggest an infectious etiology; however, a single causative organism has not been identified. Organisms isolated from stool cultures from affected babies are also isolated from healthy babies. Therefore, no single organism has been identified as the culprit responsible for triggering the disease.
 - Some experimental work suggests that translocation of intestinal flora across an incompetent mucosa may play a role in spreading disease and systemic involvement. Such a mechanism would account for the apparent protection breastfed infants have against fulminant NEC.



Necrotizing Enterocolitis

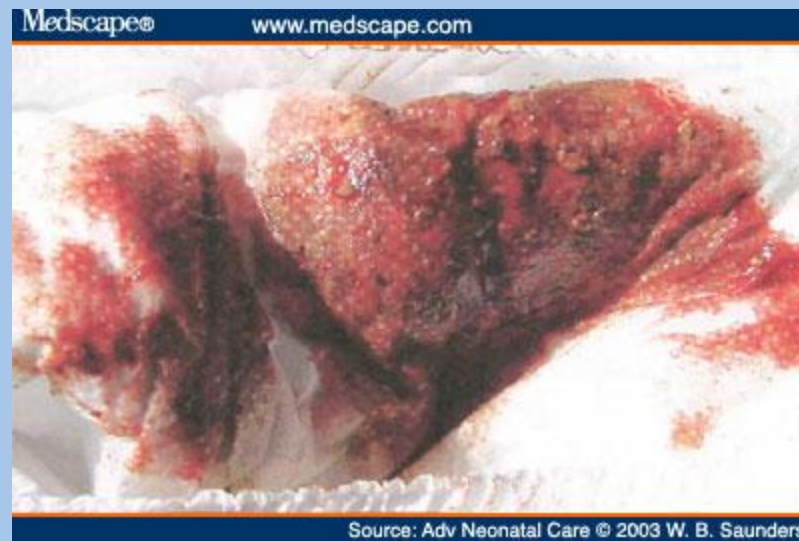Incidence

- Race: No difference based on race.
- Sex:
 - Most studies indicate that male and female babies are affected equally.
- Age:
 - NEC clearly predominates in premature infants, with incidence inversely related to birth weight and gestational age.
 - infants weighing less than 1000 g at birth have the highest attack rates.
 - rate drops dramatically to 3.8 per 1000 live births for infants weighing 1501-2500 g at birth.
 - Average age at onset in premature infants seems to be related to postconceptional age, with babies born earlier developing NEC at a later chronologic age.

Necrotizing Enterocolitis

Presenting Symptoms

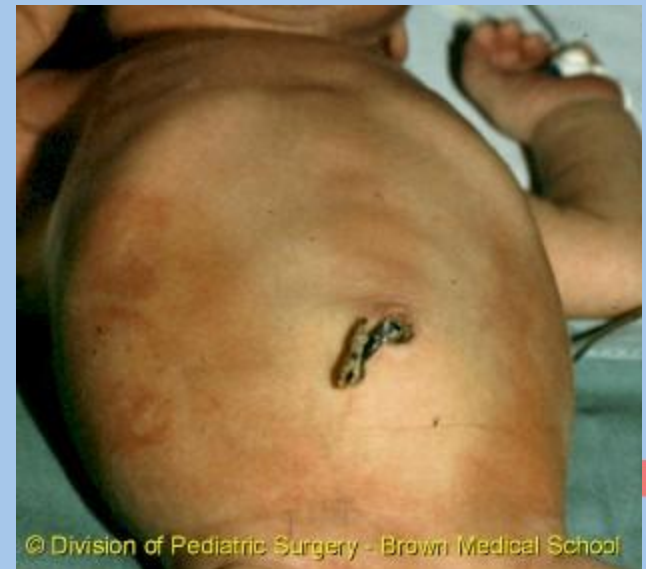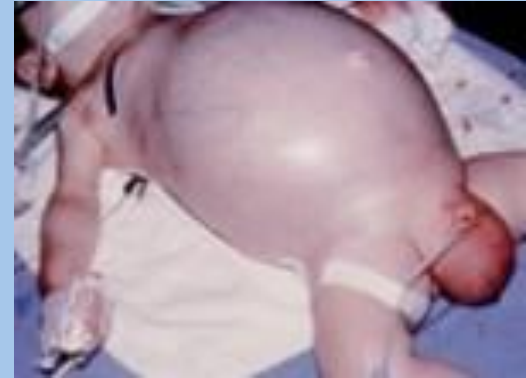- Subtle signs of feeding intolerance and "acting different" to fulminant systemic collapse.
- Abdominal distention/tenderness, increased gastric residuals and vomiting
- Systemic symptoms: increased apnea and bradycardia, lethargy, and temperature instability



Necrotizing Enterocolitis

Gastrointestinal signs can include any or all of the following:


- Increased abdominal girth
- Visible intestinal loops
- Obvious abdominal distention and decreased bowel sounds
- Change in stool pattern
- Bright red blood in the stool
- Palpable abdominal mass
- Erythema of the abdominal wall



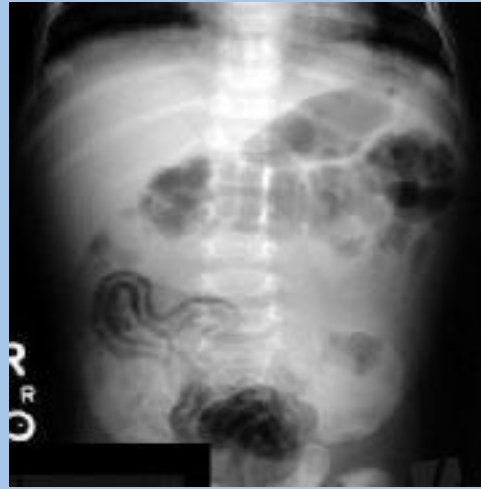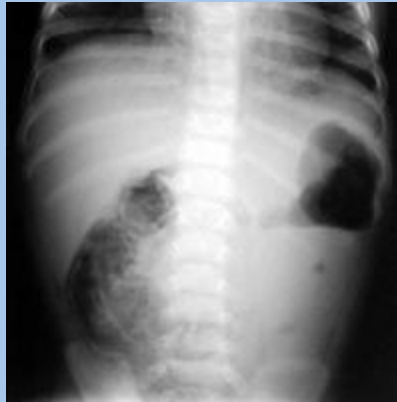
Necrotizing Enterocolitis

Work Up and Evaluation

- Laboratory Evaluation
 - Complete blood count with manual differential to look for signs of infection, anemia, and thrombocytopenia
 - Serum electrolytes to assess for metabolic acidosis
 - Blood cultures
 - ABGs
- Abdominal Radiography
 - Characteristic findings on an AP abdominal radiograph include:
 - an abnormal gas pattern
 - dilated loops
 - thickened bowel walls (suggesting edema/inflammation)
 - Pneumatosis intestinalis
 - Pathognomonic of NEC
 - It appears as a characteristic train-track lucency configuration within the bowel wall.
 - Intramural air bubbles represent extravasated air from within the intestinal lumen.
 - Abdominal free air



Necrotizing Enterocolitis



Pneumatosis intestinalis



Necrotizing Enterocolitis

Medical Care

- Treatment of NEC depends on the degree of bowel involvement and severity of its presentation.
 - Respiratory support
 - Gastric decompression
 - Fluid resuscitation
 - IV antibiotics
 - Secure venous access



Surgical Treatment

- Bedside drain placement
 - Abdominal decompression
 - Control of perforation
- Laparotomy
 - Evaluation of bowel
 - Bowel resection
 - The goal is to remove only that bowel that is fully necrosed and to leave any marginal areas in the hope that they will survive.
 - Ostomy formation
- Central access



Necrotizing Enterocolitis – Post-operative Hospital Course

- Post-operative fluid stabilization
- Management of sepsis
 - Post-operative and recurrent
- Initiation of feeding
 - Drip feeds, elemental formula
 - Distal intestinal feeding
 - Maintenance of growth – balancing TPN/IL with enteral feeds; assess for “stooling out” which affects growth
- Wound/ostomy cares
 - Wound infection, ostomy difficulties with neonates
- Pain Management
 - Sedation wean d/t long term use of narcotics & sedation medications
- Management of prematurity
 - Lung disease
- Growth & development
 - PT, OT, Speech Therapy
- Family support
 - Setbacks d/t sepsis, feeding intolerance, respiratory difficulties
- Closure of ostomy
 - Pre-op distal contrast study to evaluate for stricture
 - Post-op “butt cares”
- Transition to newborn unit (from NICU) or to home



Necrotizing Enterocolitis

Complications

- Short gut syndrome
 - CVL sepsis
 - TPN cholestasis
- Intestinal stricture
- Death



Necrotizing Enterocolitis

Family Education

- Preoperative
 - Preoperatively, counsel the family as to the available surgical options (exploration, resection & ostomy, drain, abdominal closure with palliative care).
- Postoperative
 - Home Care Issues
 - Short gut cares: CVL, TPN, G-tube, drip feeds; s/s sepsis & feeding intolerance
 - Ostomy cares (tho most stomas are closed prior to DC)



Let's take a break from all of this
technical stuff...and talk about
something really fun.....

Ostomy Care



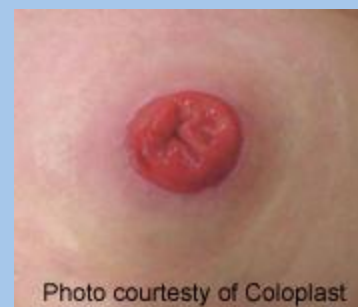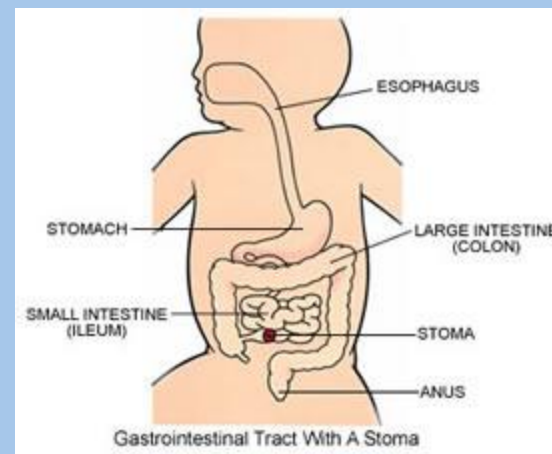
The Patient with a New Ostomy

- Begin teaching early! There is a lot to learn.
 - Ostomy manuals should be kept in the teaching file area. (English & Spanish)
 - Another option for teaching is to use the Hollister website – www.hollister.com – as they have printable teaching materials.
 - Parents will need to demonstrate pouch change and pouch emptying.



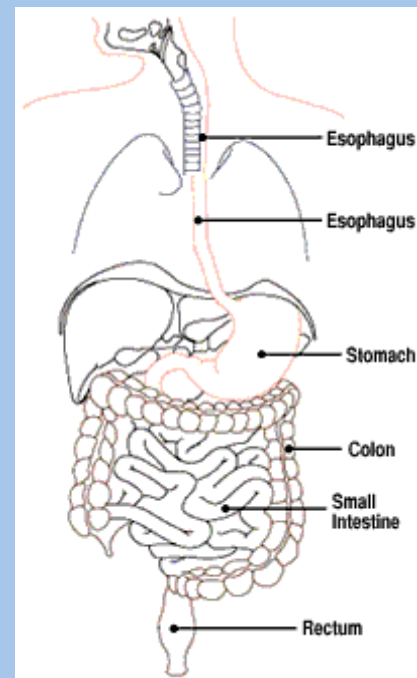
Anatomy & the Surgical Procedure

- The stoma is composed of the end of the bowel that has been brought surgically through the skin.
- It usually protrudes and has a round or oval shape.
- The tissue is usually moist and rose-colored.
- Some stomas are flush, recessed or have irregular contours that may require special pouching considerations.
- An ostomy can be created with any portion of the gastrointestinal tract.



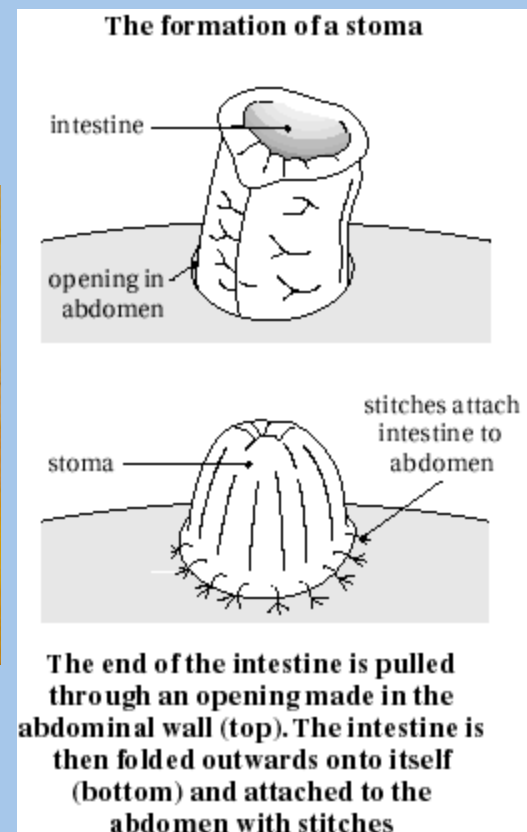
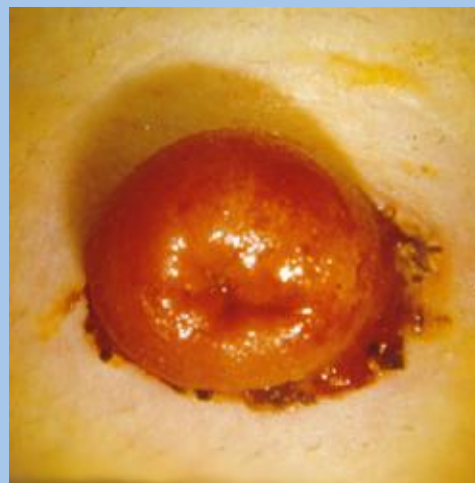
Anatomy & the Surgical Procedure

- There are multiple reasons why a child might require ostomy formation.
- There are several types of ostomies:
 - End ostomy with Hartmann's Pouch
 - Loop ostomy
 - Divided/double barrel with mucous fistula



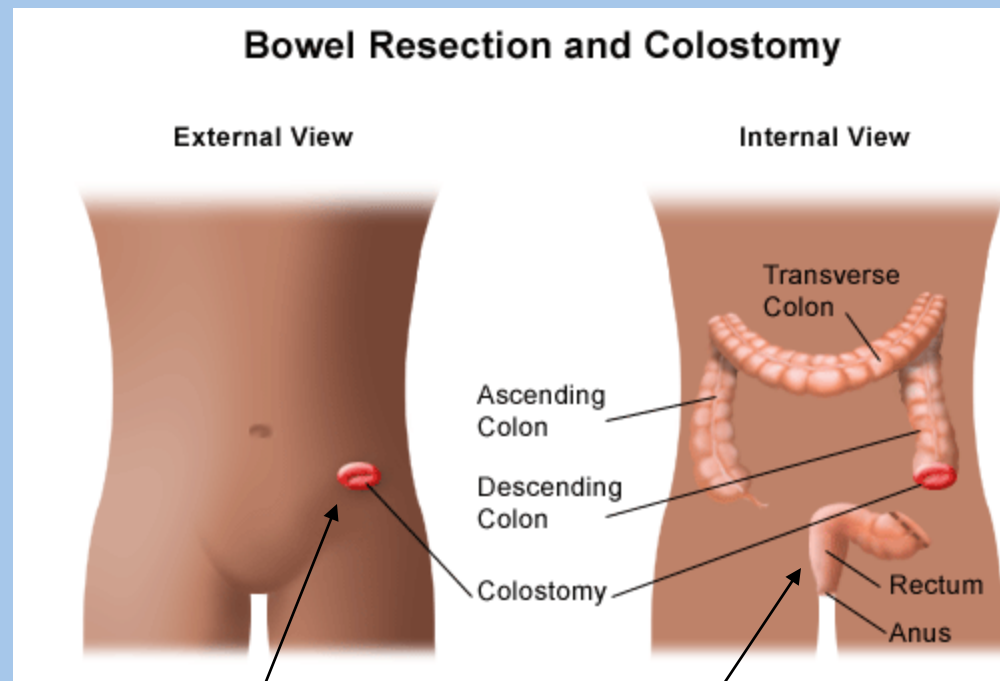
Ostomy Type – End Ostomy with Hartmann's Pouch (part 1)

- The end of the bowel is brought up through the abdominal wall (through the muscle and fat layers), everted or "cuffed", and the edges of the bowel are sutured to the surrounding skin surface.
- It is not uncommon – and not worrisome – to see the sutures (where the stoma meets the abdominal wall).
 - These will dissolve.



Ostomy Type – End Ostomy with Hartmann's Pouch (part 2)

- The second portion this procedure is the ***Hartmann's Pouch*** formation.
- The non-functional end of the bowel is sutured or stapled shut and left inside until reconnection can take place.

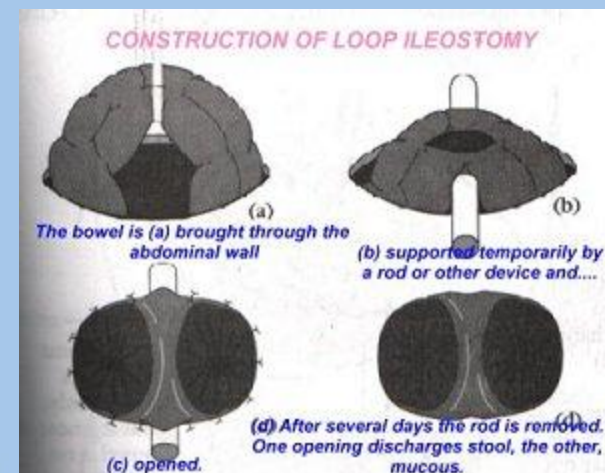
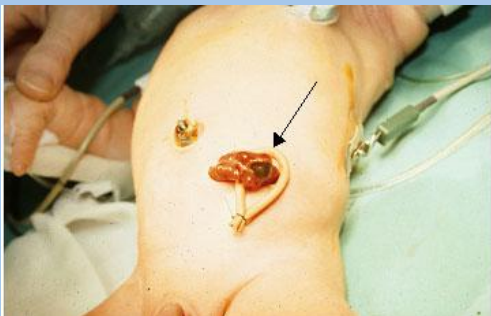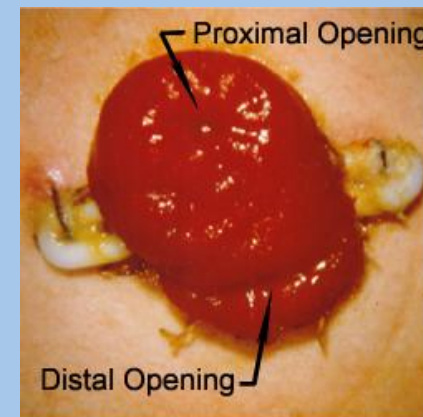


ostomy

Hartmann's
Pouch

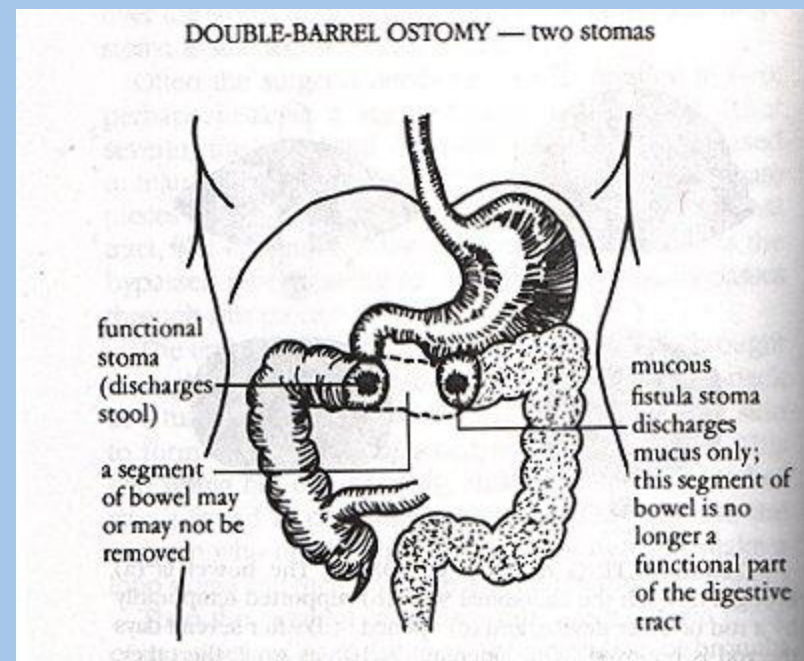
Ostomy type – Loop ostomy

- The loop ostomy will have two openings:
 - The top opening called the proximal opening is where stool is passed through.
 - The distal opening or bottom opening that is connected to the resting (downstream) portion of bowel.
- A stabilization bar may be placed at the time of surgery.
 - It is removed in 1-2 weeks.



Ostomy Type – “Divided” stoma; ostomy and mucous fistula

- *Mucous fistula*: the lower, defunctionalized part of the intestinal tract.
- This allows for mucous to pass.
- Mucous is a normal part of the body's lubrication system and it's not uncommon for small amounts of mucous to be expelled from both the stoma and the rectum.




Changing the Pouch - Overview

- Change the bag when it becomes loose. (Typical wear time is 1-3 days.)
- Try to change the bag when the child is calm and quiet.
- Try to choose a time when the stoma is less active (i.e., prior to mealtime).
- Try to wait until you have assistance!
- Use the measuring guide to cut the skin barrier to the correct size. DO NOT throw away the pattern.
- Angle the bottom of the bag down or to the side for ease of emptying.
- After placing the skin barrier and pouch, hold your hand against the barrier 1-5 minutes. The warmth and pressure will help the bag stick better.
- Parents may want to have several skin barriers cut to size ready in advance .
- If the bag won't stick it is OK to lather the area of the ostomy with diaper cream and double diaper.

Changing the Pouch – Preparation

- Set out equipment within easy reach.
- Supplies Needed:
 - New pouch
 - Scissors, pen/pencil, previous pattern or measuring guide
 - Washcloth, towel, soap, and water
 - Trash bag
 - Optional Supplies: Adhesive remover, skin protector, stomahesive paste, pink tape
- Empty pouch as normal prior to removal.



Changing the Pouch – Removing the Old Pouch

- Gently remove old pouch using warm soap and water or adhesive remover.
 - Wipe the tape (if present) surrounding the old pouch.
- Hold skin with one hand, and gently pull wafer off with the other.
- Put old pouch and other waste into a plastic bag for disposal.
- Save the pouch closure clip.



Changing the Pouch – Cleansing and Preparing the Skin

- Clean the skin and stoma with a washcloth and warm water.
 - This can be done in the shower or bath (assuming several days have passed since surgery).
- DO NOT use oils, powders, ointments, or lotions on the skin around the stoma as they will leave a film (thus causing the pouch to fall off).
- Rinse well after cleansing.
- Pat skin dry.





Changing the Pouch – Measuring the Stoma

- Measurement of the stoma is most important in obtaining good skin protection and a proper pouch fit.
- Protruding stomas require a slightly larger opening (1/8" to 1/4").
 - This slight increase in measurement can prevent stoma damage when there is stomal movement (peristaltic action).
- The gap between stoma and pouch barrier opening can be filled with a skin barrier for ileostomy care if needed.
- Flush stomas can be measured from skin line to skin line for pouch barrier openings.
- Always remember that stoma size is not absolute, fixed or permanent and should be checked periodically.

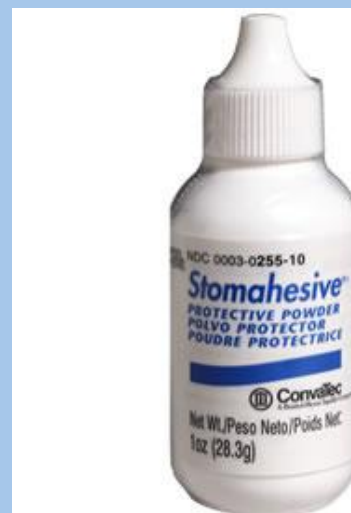Changing the Pouch – Cutting the Pouch

- Trace the opening from previous pattern or hole from the measuring guide onto the back of the pouch barrier.
- Make sure to take into account the position of the end of the pouch.
 - If patient is an infant or in bed a lot, angle pouch to side.
 - If patient is ambulatory, hang pouch over thigh (or in position preferred by patient).
- Trim opening of barrier.
 - NOTE: If using a one piece pouching system, be attentive to pouch – so that you don't accidentally cut through it.
- The edges of the opening should be smoothed with a fingertip prior to pouch application – to prevent stomal irritation.
- Double-check opening prior by placing over stoma prior to final application. Adjust opening as needed.



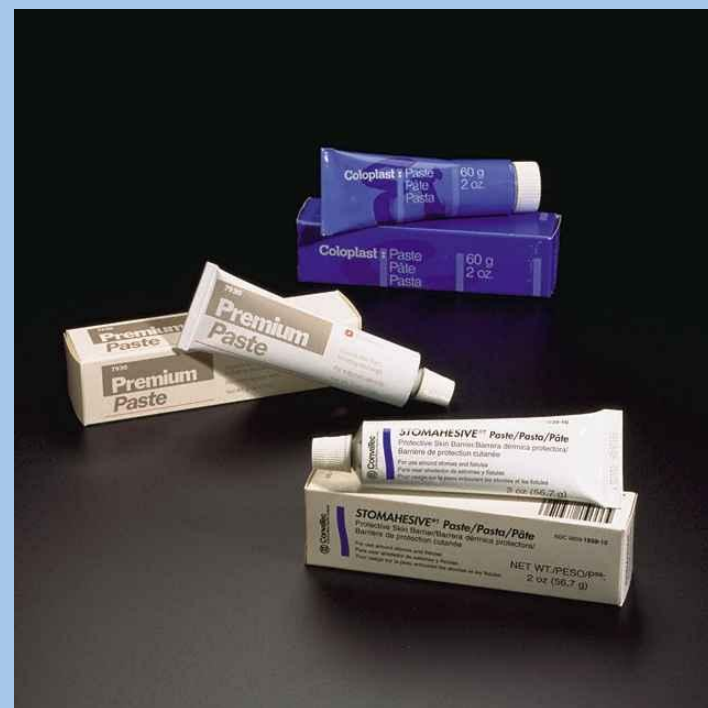Changing the Pouch – Skin Prep Products and Stomahesive Paste (part 1)

- Apply skin protector to the peristomal skin where the wafer will be (i.e., No Sting Swab, AllKare wipe) if skin is irritated.
 - These products provide a barrier film layer to help protect skin.
- Stomahesive powder may be used if skin is irritated.
 - Apply only a light dusting.
 - Increases skin barrier wafer's adhesion by drying denuded, weepy skin; helps prevent skin irritation.



Changing the Pouch – Skin Prep Products and Stomahesive Paste (part 2)

- Stomahesive paste may be applied around the wafer opening if needed to assist with seal.
 - Skin Barrier Paste Barrier paste can be compared to caulking.
 - It is a barrier in paste form and is used to fill in folds, crevices or other irregularities of the peristomal skin and create a better seal.
- The paste “controversy”
 - Not all patients need paste.
 - When using paste with a flat stoma, use a small flat layer (otherwise the pouch may be taller than the stoma itself – leading to non-adhering pouch).



Hollister Adapt Barrier Ring

Coming soon to Distribution*

- Sting-free alternative to paste.
- Can be stretched and molded to create custom shapes.
- Can be cut, bent, and stacked together to improve the fit of the skin barrier.
- For individuals with sensitive skin.
- Prolongs skin barrier wear time when used under a pouch or 2-piece skin barrier.
- When using Adapt Barrier Rings, apply them to the wafer or pouch first before attaching to the skin. Make sure the ring and skin barrier opening are of equal size, that is, the size of the stoma.



Stoma with a Mucous Fistula

- The ostomy bag can be placed over both the mucous fistula and the stoma if they are close together.
- Or the mucous fistula can be covered with Vaseline and a piece of gauze.



Emptying the Pouch

- Empty the pouch when it is 1/3-1/2 full of air or stool.
- Tip bottom of pouch upward.
- Remove pouch closure clip.
- Empty pouch into receptacle.
 - Note: It is an expensive practice to drain stool into a clean diaper.
- Clean the bag off with a tissue or baby wipe.
 - Clean both outside and inner 1-2” of pouch to remove residual stool.



Inpatient Care

- Supplies at Bedside
 - 1-2 pouches, ostomy scissors, tail closure clips, other products used for application
 - Pattern!
- Nursing Orders (Sunrise order set)
 - Emptying pouch when 1/3-1/2 full
 - Change when insecure
 - List type of pouch & last pouch change

Ile-sorb

- Ile-Sorb soluble absorbent granule packets absorb the ileostomy effluent within the pouch turning liquid into a semi-solid gel, evenly distributing the weight, reducing noise, and preventing leakage.
- Absorbs 250ml of effluent; for small infants, only part of a package is needed



Family Education

- Parent Teaching
 - Give teaching materials to parents
 - Explain procedures (emptying/changing) to parents
 - Hands-on by patient and family – early on
 - Patient and family must be independent in emptying pouch prior to being DC'ed
 - Patient & family should see one pouch change and re-demo a pouch change prior to DC
 - Need to figure this into post-op planning – as most pouches stick for several days.

Resources

- www.hollister.com
- www.convatec.com
- www.coloplast.com
- Parents can call any ostomy company to request samples – if their products are not working well (in addition to alerting Surgery Clinic).
- Home nursing should be set up prior to discharge.
- Patients should follow up with their surgeon 1-2 weeks following discharge.
 - Surgery Clinic: 414-266-6420

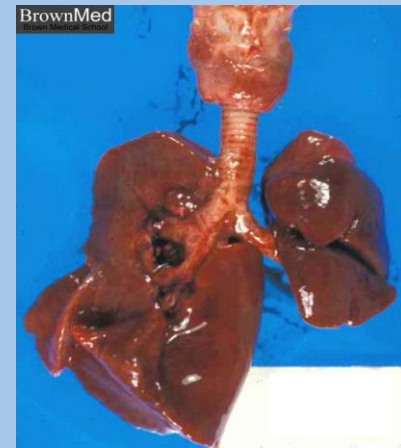

Back to the complicated stuff...



Congenital Diaphragmatic Hernia

- The short version...
- The presence of the herniated viscera within the chest leading to a variable degree of pulmonary hypoplasia associated with a decrease in the pulmonary vasculature and dysfunction of the surfactant system.



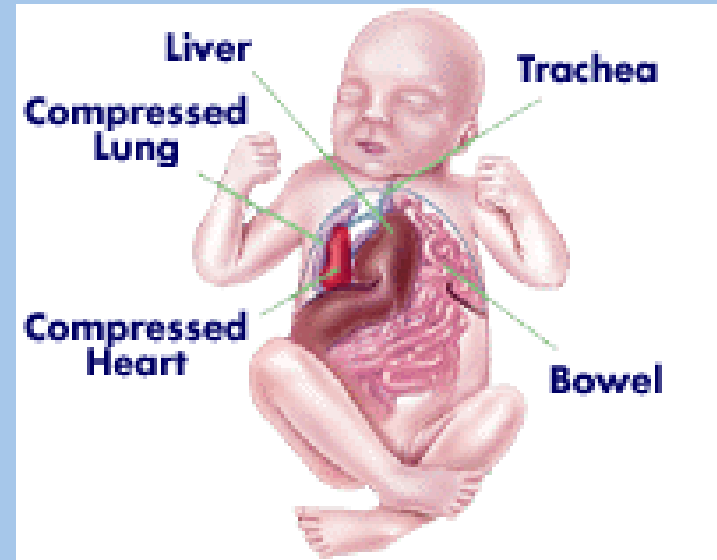
Congenital Diaphragmatic Hernia

- Incidence:
1 of every 2000-4000
- Male:Female - 1.5:1
- Associated Defects:
 - Karyotype abnormalities – 4%
 - trisomy 13, trisomy 18, and tetrasomy 12p mosaicism.
- Age: A disorder of the newborn period, as many as 10% of patients may present after the newborn period and even during adulthood.



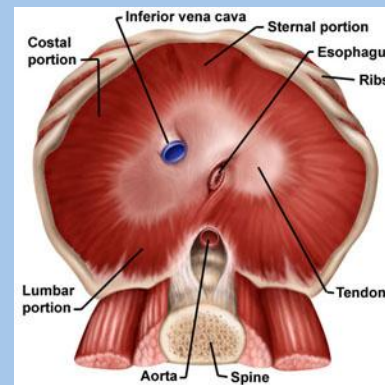
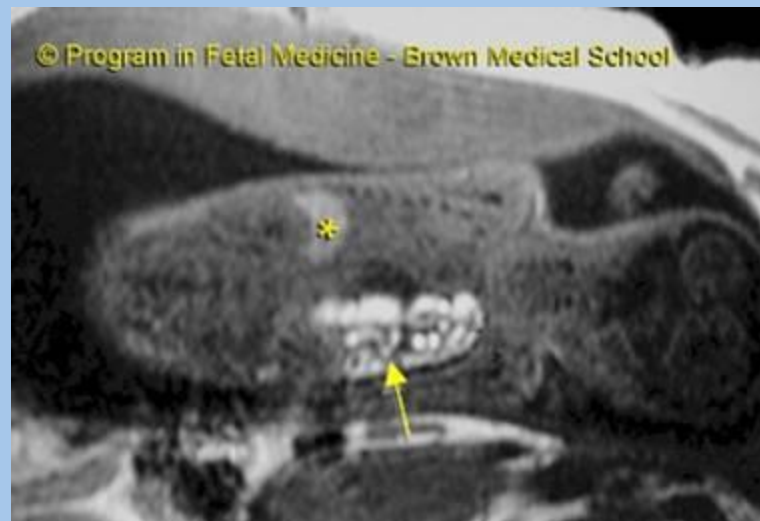Congenital Diaphragmatic Hernia

- Embryology
 - The cause of CDH is largely unknown.
 - Failure of diaphragmatic closure
 - Components: septum transversum, pleuroperitoneal membrane, dorsal mesentery of esophagus, lateral body walls



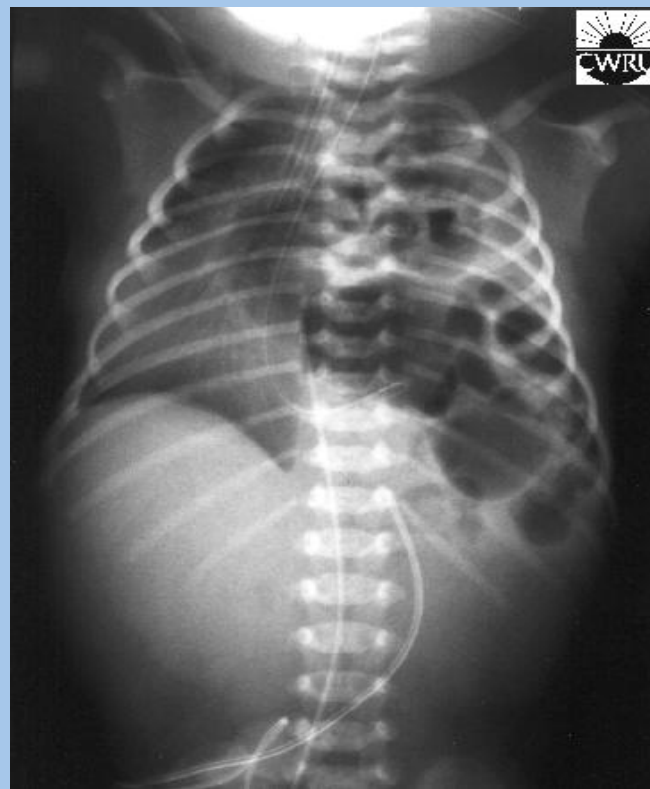Congenital Diaphragmatic Hernia

- The diaphragm normally forms between the 7th and 10th week of pregnancy. The esophagus, the stomach, and the intestines are also developing at this time.
- For unclear reasons in babies with CDH, the muscle does not form completely.



Congenital Diaphragmatic Hernia

- Clinical Presentation & Physical Examination
 - Cyanosis and respiratory distress
 - Scaphoid abdomen, respiratory distress, and cyanosis
 - Poor air entry on affected side with a shift of cardiac sounds over the right chest



Congenital Diaphragmatic Hernia

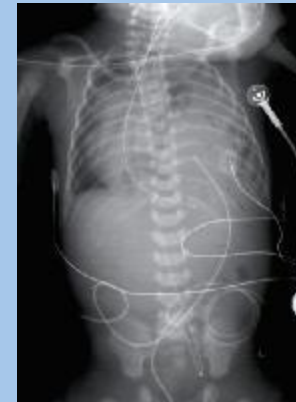- Newborn Management
 - Respiratory support
 - Endotracheal intubation, ventilation, oxygen delivery
 - Goal: Optimize oxygenation while avoiding barotrauma.
 - Treatment of pulmonary hypertension
 - Arterial and venous access
 - Gastric decompression
 - Placement of orogastric tube.
 - Gastric and intestinal distension can compromise ventilatory efforts
 - Fluid Resuscitation
 - Prevention of hypothermia
 - Diagnosis and work-up of associated anomalies



Congenital Diaphragmatic Hernia

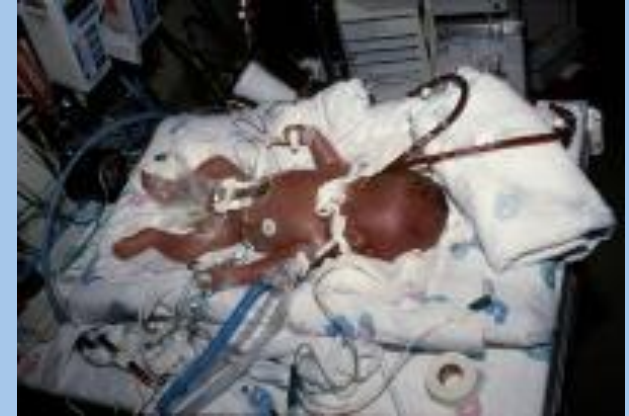
Diagnostic Imaging

- Chest X-Ray
 - Typical findings in left-sided posterolateral CDH include air- or fluid-filled loops of the bowel in the left hemithorax and shift of the cardiac silhouette to the right.
- ECHO
 - Associated cardiac anomalies is high (up to 25%)
- Head Ultrasound
 - evaluation of intraventricular bleeding or infarct (esp. if patient is being considered for ECMO)
- This is a radiograph of a 1-day-old infant with a moderate-sized congenital diaphragmatic hernia. Note the air- and fluid-filled bowel loops in the left chest, the moderate shift of the mediastinum into the right chest, and the position of the orogastric tube.



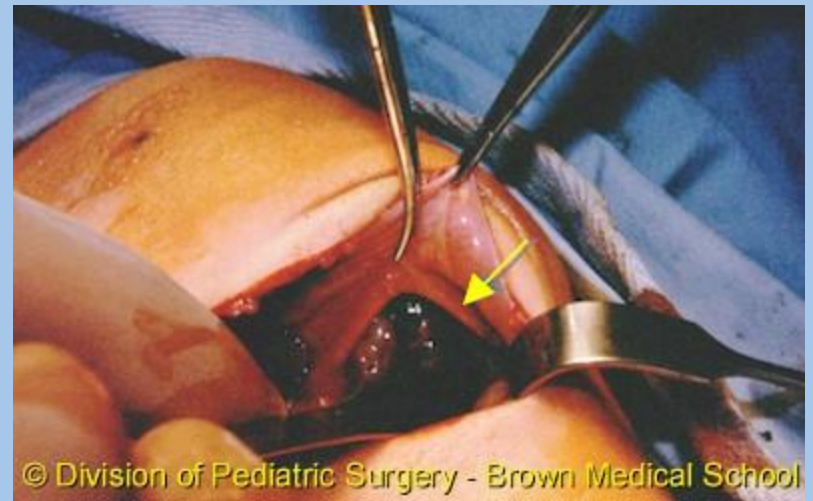
Congenital Diaphragmatic Hernia

- Surgical Supportive Care
 - ECMO
 - The ECMO machine continuously pumps blood from the patient through a "membrane oxygenator" that imitates the gas exchange process of the lungs, i.e. it removes carbon dioxide and adds oxygen. Oxygenated blood is then returned to the patient.



Congenital Diaphragmatic Hernia

- Surgical Treatment
 - Delayed surgical approach enables preoperative stabilization allowing for resolution of pulmonary hypertension.
 - Closure of defect with/without patch
 - Thoracoscopic vs. Laparoscopic/open laparotomy



Congenital Diaphragmatic Hernia

- Postoperative care
 - Cardiopulmonary support
 - Nutritional support
 - Parenteral support early
 - Conversion to enteral feeds with return of bowel function & when respiratory status allows
 - Comfort
- Complications
 - Immediate
 - Respiratory insufficiency
 - Wound infection
 - Late
 - chronic lung disease
 - growth failure
 - gastroesophageal reflux
 - neurodevelopmental delay
- Mortality
 - Mortality – 60%
 - This is partially because of the hidden mortality for this condition. Hidden mortality refers to infants with CDH who are so severely affected that they die prior to transfer to a surgical site.
 - Outcome in patients with late presentation of CDH is extremely good, with low or no mortality.

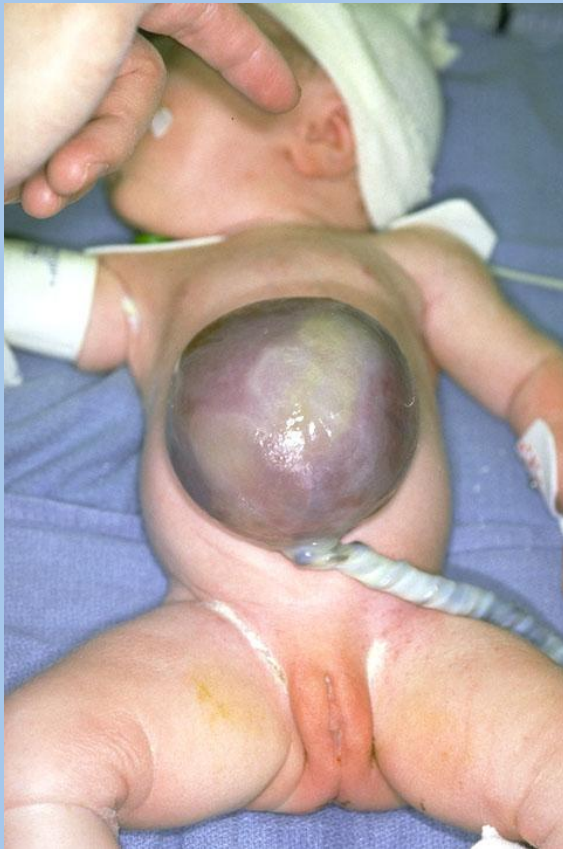

What is an abdominal wall defect?

- A disorder of the umbilical region either due to persistence of structures, which usually obliterate before birth, or failure of closure of the umbilical ring.



Omphalocele



- Description
 - Central abdominal defect through which both hollow and solid abdominal viscera can pass.
 - Defect is covered by a membrane of amnion externally and peritoneum internally.
 - The umbilical cord inserts into the membrane.
 - Defects of varying size - 2 to 10 cm
 - Protruding organs: small intestine, stomach, liver, spleen, colon



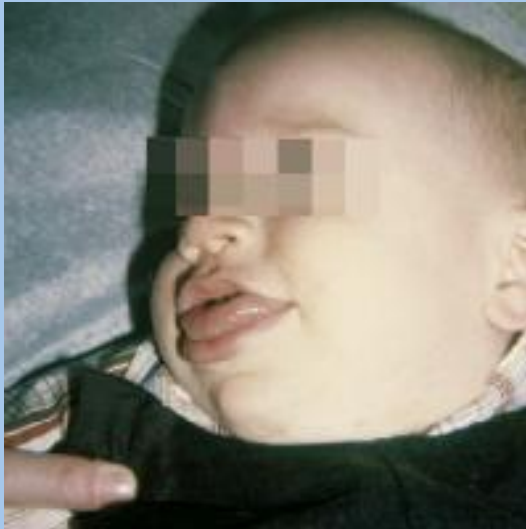Omphalocele

- Incidence: 1 in 4000 births
- Male = Female
- Associated Defects:
(55-70% of cases)
- Chromosomal Anomalies - 40%
 - Trisomy 13, 18, 21
- Congenital Heart Disease - 25%
 - Ventricular Septal Defect
- Gastrointestinal disorders
- Neurologic disorders
- Genitourinary anomalies



Omphalocele

Beckwith-Wiedemann Syndrome

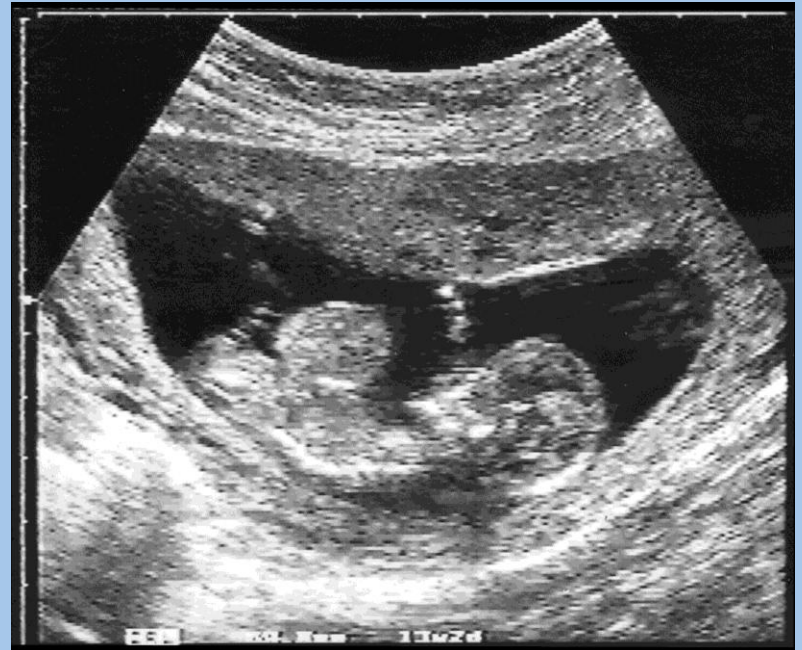

- A genetic disorder that comprises multiple congenital anomalies.
 - alteration on the short arm of chromosome 11
- Features
 - Macroglossia with a protruding mandible
 - Gigantism
 - Pancreatic hyperplasia = hypoglycemia
 - Visceromegaly
 - Craniofacial anomalies




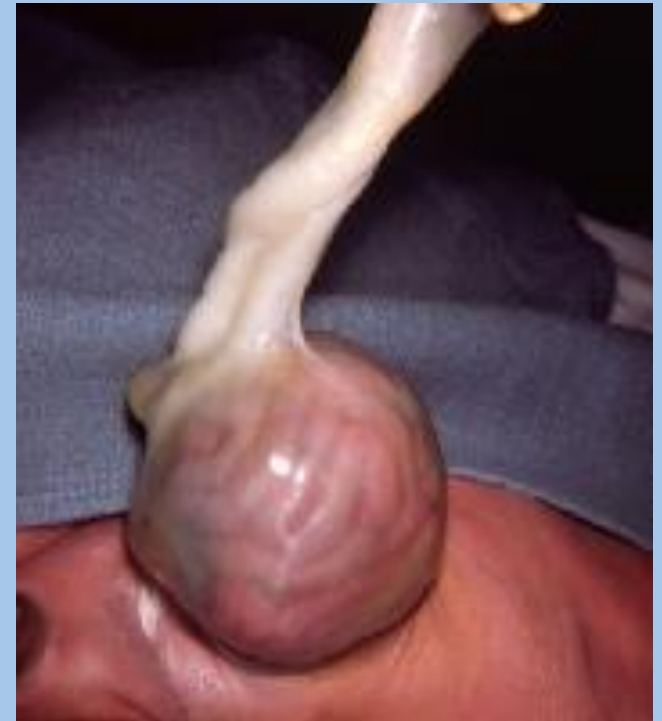
Omphalocele

- Prenatal Diagnosis
 - Elevated maternal serum alpha-fetoprotein value
 - Polyhydramnios
 - Amniocentesis for evaluation of other anomalies
 - Targeted ultrasound for further anomalies
- Sagittal antenatal scan in a 13-week-old fetus shows an omphalocele with liver.



Omphalocele

- Clinical Presentation
 - Herniation of abdominal wall at umbilicus
 - Abdominal contents covered by membrane
- Physical Examination
 - Assess sac for rupture
 - Assess viability of sac contents
 - Assess for associated defects



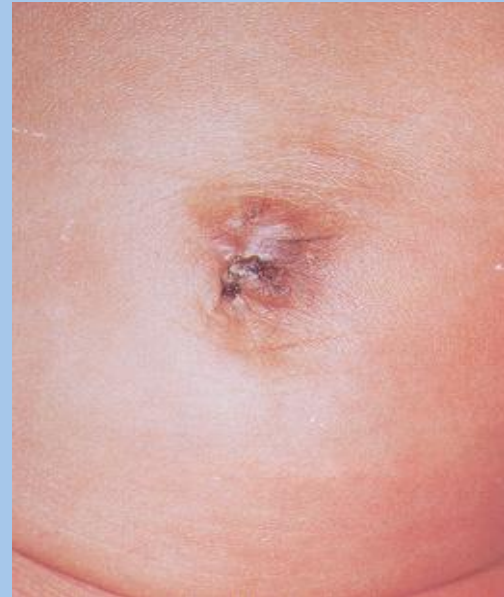
Omphalocele

- Newborn Management
 - Respiratory support
 - Endotracheal intubation, ventilation, oxygen delivery
 - Arterial and venous access
 - Protection of defect
 - Gastric decompression
 - Placement of orogastric tube.
 - Gastric and intestinal distension can compromise ventilatory efforts
 - Fluid Resuscitation
 - Broad spectrum antibiotic coverage
 - Prevention of hypothermia
 - Diagnosis and work-up of associated anomalies



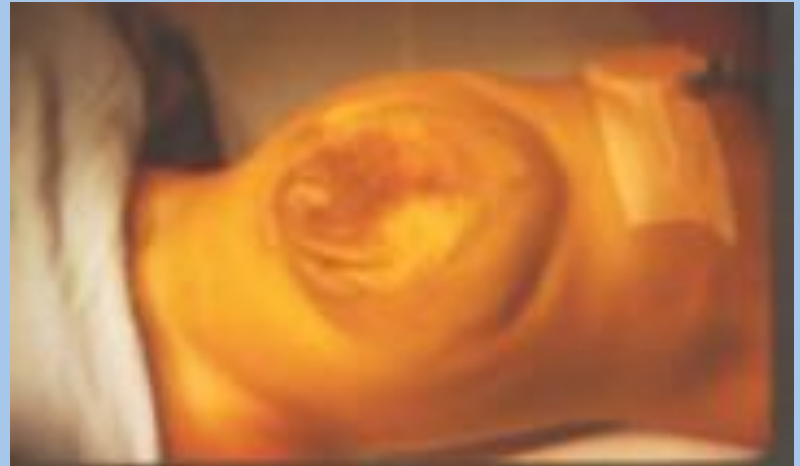Omphalocele

- Treatment - Operative
 - Return abdominal contents to abdominal cavity.
 - Complete closure of abdominal wall including musculature, fascia, and skin.
 - This can be done in primary or delayed manner.
 - Intraoperative assessment of intraabdominal pressure and cardiopulmonary compliance is essential.



Omphalocele

- Treatment -
Nonoperative
 - When surgical treatment is not feasible, a covered ventral hernia can be established by using topical agents.
 - Care must be avoided to prevent toxicity and side-effects from treatment.



Omphalocele

- Postoperative care
 - Cardiopulmonary support
 - Nutritional support
 - Parenteral support early
 - Conversion to enteral feeds with return of bowel function
 - Comfort
- Complications
 - Immediate
 - Respiratory insufficiency
 - Abdominal compartment syndrome
 - Wound infection
 - Late
 - Sepsis
 - TPN cholestasis
- Mortality
 - Associated comorbid condition: 30% mortality
 - No associated condition: Minimal mortality

Omphalocele

- Nursing Responsibilities
 - Preoperative
 - Protect defect
 - Prevent hypothermia
 - Comfort of patient
 - Gastric decompression
 - Assess for hypoglycemia
 - Prevent infection
 - Respiratory support
 - Postoperative
 - Assessment of cardiopulmonary function
 - Comfort of patient
 - Fluid therapy
 - Assessment of wound
 - Protection of silo (if present)
 - Aseptic maintenance of venous access

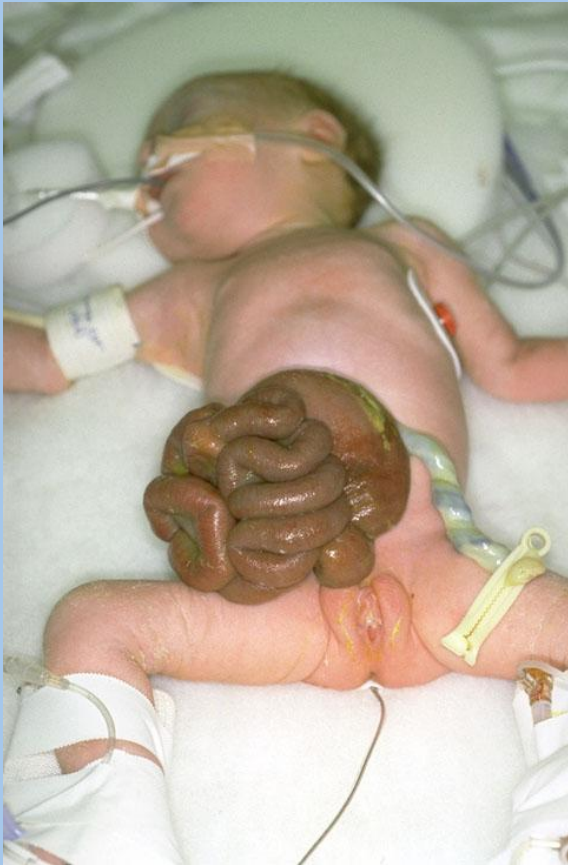

Omphalocele

- Family Education
 - Prenatal
 - Preoperative
 - Postoperative
 - Long Term Issues
- "Mothers Of Omphaloceles"
<http://www.omphalocele.com/>
- Long Term Issues
 - Gastroesophageal reflux
 - Ventral hernia repair required for those treated nonoperatively
 - Incisional hernia
 - Inguinal hernia
 - Intestinal obstruction
 - Prolonged pulmonary issues
 - Issues related to other anomalies



Gastroschisis



- Description
 - Smaller defect - <4cm
 - Defect occurs to the right of intact umbilical cord
 - Uncovered viscera
 - Protruding organs – small intestines



Gastroschisis

Incidence

- Overall incidence: 1 in 6000 to 10,000 births
- Incidence in mothers under age 20: 7 in 10,000 births
- Male = Female
- First born - 70%

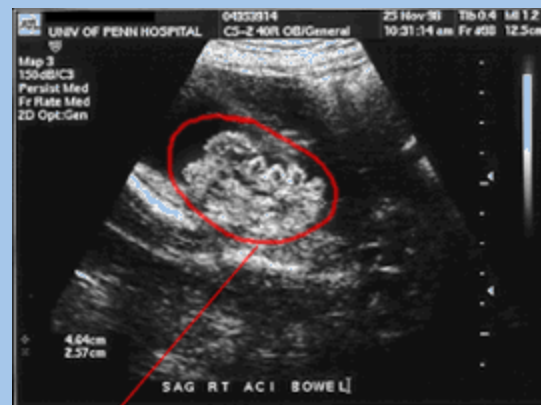Associated defects

- Intestinal atresia (jejunoileal)
- Malrotation
- Usually not associated with chromosome anomalies
- In utero midgut volvulus
- Intrauterine growth retardation
 - Abnormal fetal nutrient balance



Gastroschisis

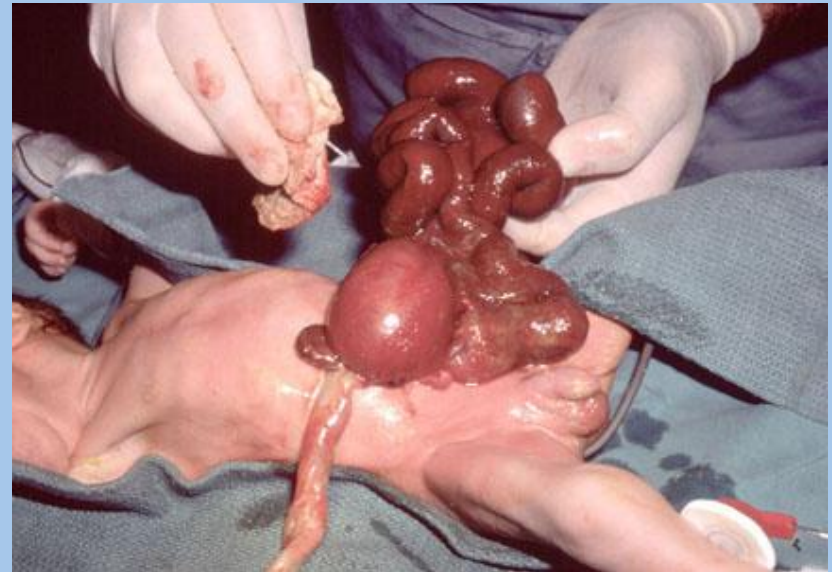
- Prenatal Diagnosis
 - Elevated maternal serum alpha-fetoprotein value
 - Polyhydramnios
 - Targeted ultrasound to assess appearance of eviscerated bowel
- Prenatal Ultrasound
 - Free-floating loops of bowel in the amniotic fluid



Fetal ultrasound showing bowel protruding from abdominal wall defect.

Gastroschisis

- Clinical Presentation
 - Herniated abdominal contents to right of umbilical cord
- Physical Examination
 - Assess viability of extruded intestine
 - The bowel appears thickened, matted, and shortened



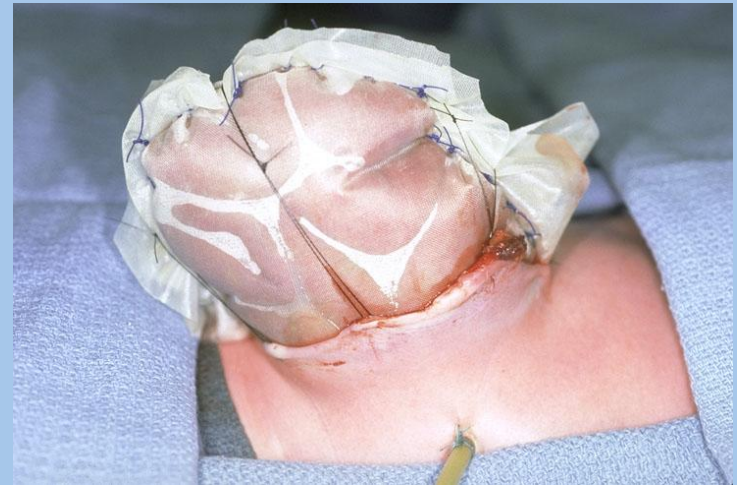Gastroschisis

- Newborn Management
 - Respiratory support
 - Endotracheal intubation, ventilation, oxygen delivery
 - Arterial and venous access
 - Protection of defect
 - Apply sterile saline soaked gauze to defect.
 - Avoid excessively wet dressing – this leads to bowel maceration.
 - Apply barrier over saline soaked gauze & lower half of baby (bowel bag, saran wrap).
 - This prevents heat loss.
 - Care should be taken to maintain circulation to exposed intestines
 - Inappropriate coverage may induce torsion of vascular pedicle.
 - Gastric decompression
 - Placement of orogastric tube.
 - Gastric and intestinal distension can compromise ventilatory efforts
 - Fluid Resuscitation
 - Fluid requirements in gastroschisis 2.5x normal
 - Broad spectrum antibiotic coverage
 - Blood culture
 - Prevention of hypothermia



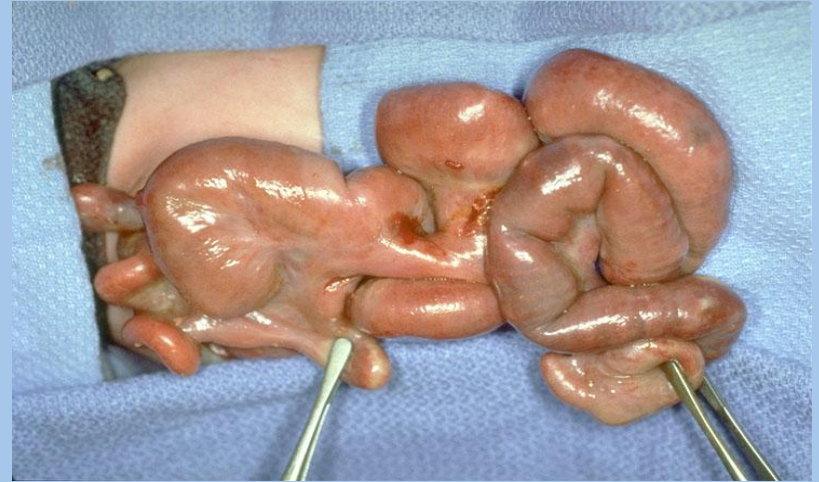Gastroschisis

- Surgical repair on first day of life
 - Primary repair
 - Delayed primary repair – Silo
 - In ability to accomplish complete reduction
 - Progressive reduction without bowel compromise
 - Reduction to fascial approximation may be reached in 1-2 weeks time
 - Potential placement of central venous line and/or gastrostomy tube



Gastroschisis

- Intestinal atresia
 - Bowel atresia can be successfully managed by nasogastric decompression, allowing in eventual reanastomosis.
 - Delays allow for resolution of peel and nutritional optimization.



Gastroschisis

- Nursing Responsibilities – Preoperative
 - Protection of defect
 - Taking care to prevent vascular compromise of an unsupported defect
 - Prevention of hypothermia
 - Comfort of patient
 - Gastric decompression
 - Fluid resuscitation
 - Prevent infection
 - Respiratory support
- Nursing Responsibilities – Postoperative
 - Assessment of cardiopulmonary function
 - Comfort of patient
 - Fluid therapy
 - Assessment of wound
 - Protection of silo (if present)
 - Aseptic maintenance of venous access
 - Gastric decompression
 - Developmental stimulation



Gastroschisis

- Postoperative care
 - Cardiopulmonary support
 - Gastric decompression
 - Clearly note if unrepaired atresia present
 - Central access
 - Prevention of sepsis
 - Nutritional support
 - Parenteral support
 - Comfort
- Enteral Feeding
 - Contact with amniotic fluid causes severe damage to the bowel which results in abnormalities of fetal bowel function.
 - Return of bowel function may take 4-6 weeks.
 - Prolonged bowel dysmotility or bowel loss due to intestinal atresia may necessitate long term TPN.



Gastroschisis

- Complications
 - Immediate
 - Respiratory insufficiency
 - Wound infection
 - Late
 - Sepsis
 - TPN cholestasis
- Complications
 - Necrotizing enterocolitis
 - Bowel perforation
- Mortality: 10%



Gastroschisis

- Family Education
 - Prenatal
 - Preoperative
 - Postoperative
 - Long Term Issues
- Long Term Issues
 - Gastroesophageal reflux
 - Ventral hernia repair required for those treated nonoperatively
 - Incisional hernia
 - Inguinal hernia
 - Intestinal obstruction
 - Prolonged pulmonary issues
 - Issues related to other anomalies



Other Abdominal Wall Defects

- Pentalogy of Cantrell
 - Omphalocele with ectopic heart
- Cloacal Exstrophy
 - Omphalocele, hemi-bladders, imperforate anus, abnormalities of sexual structures & external genitalia
 - “Vesicointestinal fissure”
- Bladder Exstrophy
 - Bladder plate protruding beneath umbilical cord, separate pubic bones, abnormalities of external genitalia
- Prune Belly Syndrome
 - Abdominal wall laxity
 - Urinary tract abnormalities



Prenatal Counseling: Any surgical diagnosis

- Prenatal detection of surgical defects allows parents time to discuss and plan delivery and postnatal management options with an obstetrician, neonatologist, and pediatric surgeon prior to birth.
- Predelivery consultations with advanced practice nurses associated with a “fetal concerns” program and tours of the NICU can also assist the parents with their information gathering.
- There are proven advantages to the baby if skilled pediatric care is available at the time of delivery.



General Surgical Conditions in the Neonate: Final Thoughts

- Supportive care for both infant and family are necessary.
- The hospital course may be challenging and lengthy.
- Prepare family for both inpatient and long term issues.
- Assist with transition from NICU to newborn care unit to home.
- Discuss potential readmissions.
- Stress long-term follow up.
- The family will always have support – they do not need to “walk alone”.

